

Enhanced Cortical Activation in the Contralateral Hemisphere of Chronic Stroke Patients in Response to Motor Skill Challenge

Judith D. Schaechter^{1,2} and Katherine L. Perdue^{1,2}¹MGH/MIT/HMS Athinoula A. Martinos Center for Biomedical Imaging, Charlestown, MA 02129, USA and ²Department of Radiology, Harvard Medical School, Boston, MA, USA

The brain processes involved in the restoration of motor skill after hemiparetic stroke are not fully understood. The current study compared cortical activity in chronic stroke patients who successfully recovered hand motor skill and normal control subjects during performance of kinematically matched unskilled and skilled hand movements using functional magnetic resonance imaging. We found that cortical activation during performance of the unskilled movement was increased in the patients relative to controls in the contralateral primary sensorimotor cortex. Performance of the skilled movement elicited increased activation in the patients relative to controls in the contralateral primary sensorimotor cortex, ventral premotor cortex, supplementary motor area/cingulate, and occipitoparietal cortex. Further, the activation change in the contralateral occipitoparietal cortex was greater in the patients relative to controls with the increase in motor skill challenge. Kinematic differences, mirror movements, and residual motor deficits did not account for the enhanced activation in the contralateral cortices in the patients. These results suggest that activation in the contralateral cortical network was enhanced as a function of motor skill challenge in stroke patients with good motor recovery. The findings of the current study suggest that successful recovery of motor skill after hemiparetic stroke involves participation of the contralateral cortical network.

Keywords: cerebral ischemia, functional recovery, motor tasks, MRI/fMRI, neuroplasticity

Introduction

Stroke often causes hemiparesis due to direct damage and/or secondary functional disruption of brain areas controlling movement. Recovery of motor function, when it occurs, typically starts with regaining limb synergies characterized by gross, undifferentiated movements of the stroke-affected limb (Twitchell 1951; Brunnstrom 1966). Recovery may proceed by regaining the ability to perform skilful, nonsynergistic limb movements in which intralimb joints can be controlled independently. Recovery of hand motor function also follows this trajectory, with early restoration of synergistic movements in which the digits can grasp and release in unison and later restoration of dexterous, nonsynergistic movements in which the digits can be moved independent of one another. Recovery of nonsynergistic hand movements is critical to functional use of the hand in daily activities, such as tool usage and object manipulation.

The changes in brain activity mediating recovery of motor function after stroke are beginning to be unraveled. Early after hemiparetic stroke in patients, performance of a gripping task (i.e., a synergistic movement) by the affected hand has been shown to increase activity in several cortices within the

ipsilesional and contralateral hemispheres to a greater degree than in normal control subjects (Ward et al. 2003a). Progressive normalization of cortical activity elicited by hand gripping appears to occur during the recovery process in stroke patients (Ward et al. 2003a). Further, cortical activity associated with hand gripping in chronic stroke patients with good motor recovery has been shown to be indistinguishable from that in normal controls (Ward et al. 2003b). In contrast, during index finger or sequential finger tapping (i.e., nonsynergistic movements), cortical activity in chronic stroke patients with good motor recovery has been observed to be enhanced relative to that in normal controls, most commonly in the primary motor cortex, premotor cortex, and parietal cortex of the contralateral hemisphere (Chollet et al. 1991; Weiller et al. 1993; Cramer et al. 1997; Cao et al. 1998; Foltys et al. 2003; Gerloff et al. 2006; Lotze et al. 2006). These observations suggest that differences in motor task-related cortical activity between well-recovered stroke patients and normal controls are more pronounced as the skill demanded by the motor task is increased. However, the relationship between cortical activity and motor skill challenge in stroke patients has not been tested directly. This is partly due to previous studies, with the exception of a few, having stroke patients perform only a single motor task, either synergistic or nonsynergistic. In the few studies in which more than one motor task was performed (Cramer et al. 2001; Foltys et al. 2003; Nair et al. 2007), comparison between resultant activation patterns was confounded by the tasks not being matched for kinematic parameters of performance (e.g., force, amplitude, frequency, range of motion, number of body segments moved, and which body segments moved).

The purpose of the current study was to gain insight into the cortical processes involved in the restoration of motor skill after stroke. To meet this goal, cortical activity in chronic stroke patients who successfully recovered motor skill was compared with that in normal control subjects using functional magnetic resonance imaging (fMRI). The fMRI was conducted while the subjects performed a pair of kinematically matched hand motor tasks that were developed by Ehrsson et al. (2002) to examine differences in the neural control of synergistic versus nonsynergistic movements in normal healthy subjects. The synergistic task involved movement of all 5 digits in unison, whereas the nonsynergistic task involved independent movement of the thumb relative to the unified movement of the other 4 digits. As the nonsynergistic task involved independent digit movement, this task required more skill than the synergistic task. Understanding the effect of motor skill challenge on cortical activation in stroke patients could ultimately lead to the development of interventions aimed at maximizing motor recovery after hemiparetic stroke.

Materials and Methods

Subjects

Ten patients with chronic stroke, former inpatients at Boston area hospitals, were enrolled (Table 1). These patients fulfilled the following inclusion criteria: 1) first-ever ischemic stroke that spared the hand region of the primary motor cortex; 2) stroke incurred ≥ 6 months earlier; 3) acute unilateral loss of hand strength to ≤ 4 on the Medical Research Council (MRC) scale (0-5, 5 = normal) (Medical Research Council 1976) based on physician notes entered into the medical record of the initial hospitalization within ~ 24 h after stroke; and 4) good hand motor function at the time of study enrollment, determined by the ability to competently perform the synergistic and nonsynergistic hand motor tasks applied during fMRI. Exclusion criteria were: 1) prior or subsequent symptomatic stroke; 2) language or cognitive deficit that would impair cooperation with study procedures; 3) significant somatosensory (light touch or proprioception) deficit of the stroke-affected hand; 4) other disorder that impaired motor function of the stroke-affected hand; and 5) contraindication to magnetic resonance imaging. Enrolled patients were evaluated for their premorbid hand preference using the Edinburgh Inventory (Oldfield 1971). All patients had received and completed physical rehabilitation after their stroke.

Ten control subjects with no history of stroke and a normal neurological examination were also enrolled. A control subject was matched, as closely as possible, to each stroke patient first by handedness (premorbid for patients), second by age, and third by gender (Table 1). This matching was done because handedness (Dassonville et al. 1997; Volkmann et al. 1998) and age (Mattay et al. 2002; Ward and Frackowiak 2003) have been shown to affect brain activity during performance of motor tasks. Further, gender may influence brain activity during visuo-motor processing (Gorbet and Sergio 2007). A separate cohort of 10 healthy normal subjects was enrolled to evaluate their perception of challenge to perform the hand motor tasks applied during fMRI (see Supplementary Material).

All subjects provided written informed consent in accordance with the Human Subjects Committee of the Partners Institutional Review Board.

Testing of Hand Motor Function

Motor function of the right and left hands of subjects was assessed using 2 tests. The maximum speed of unilateral index finger tapping was measured. The subject sat in a chair with the forearm pronated and hand resting on a tabletop, then extended the index finger, repeatedly and as fast as possible, to a marker 2 inches off the table in two 10-s trials. Fine manual dexterity was tested using the Purdue Pegboard test in three 30-s trials (Tiffin and Asher 1948; Desrosiers et al. 1995). Test scores were averaged over trials. Average test scores for the stroke-affected hand of patients and comparable hand of controls were normalized to percent of the contralateral hand. Between-group differences in test scores were evaluated by 2-tailed, unpaired *t*-tests, with alpha set to 0.05 (StatView, version 4.5). A principal component analysis was performed

with both sets of test scores from the patients using MATLAB (The Mathworks, v6.5.1). The first principal component, which accounts for the greatest percentage of the variability within the data, was taken to represent overall hand motor function for each patient. Subsequent analyses utilized the first principal component to examine the relationship between overall hand motor function and brain activation across the patients.

Motor Tasks during fMRI

The stroke-affected hand of patients was used to perform the motor tasks during fMRI. Because the affected hand among patients was of mixed dominance, we had the handedness-matched control subjects perform the motor tasks with their comparable hand (e.g., left hand of a right-hand dominant control matched to a right-hand dominant patient with left hemiparesis). This patient-control matching procedure eliminated potential confounds in brain activation related to hand dominance (Dassonville et al. 1997; Volkmann et al. 1998).

Subjects performed unilaterally kinematically matched synergistic and nonsynergistic motor tasks that have been described previously (Ehrsson et al. 2002). The synergistic motor task required the 5 digits flex and extend in unison. The nonsynergistic motor task required that thumb flexion was accompanied by unified extension of the other 4 digits, and that thumb extension was accompanied by unified flexion of the other 4 digits. The nonsynergistic motor task involved independent movement of the thumb relative to movement of the other 4 digits and, therefore, was more skilful than the synergistic task. Both the synergistic and nonsynergistic motor tasks were performed at 0.25 Hz (1 cycle per 4 s) with the digits moving through their full range of motion. The perceived level of challenge to perform each of the motor tasks was tested (2-tailed paired *t*-test) in the separate cohort of healthy normal subjects using a visual analogue scale (Wewers and Lowe 1990; see Supplementary Material). Movement epochs (22.5 s \times 5) alternated with rest epochs (22.5 s \times 6) in which the hand fully relaxed. The synergistic and nonsynergistic motor tasks were performed in separate functional runs, with the order of runs randomized across subjects. Subjects were not able to see their hands during scanning. Conditions were cued by visual stimuli generated by a Macintosh G3 iBook running MacStim software (version 2.6). The visual stimuli were back projected onto a translucent screen that subjects viewed via a tilted mirror. Movement stimuli were schematic representations of a hand that alternated every 2 s between the 2 movement phases and were colored green for the 22.5-s epoch, except for the last 2.5 s when the schematic changed to red to cue preparation to stop moving. Stimuli cueing for the synergistic and nonsynergistic movements were the same size. Stimuli cueing rest were shaped as an asterisk, sized similar to the movement stimuli, and alternated between being colored blue and red at the same frequency as the movement stimuli (every 2 s). Before scanning, subjects were trained on these tasks until they could be performed comfortably (usually 10 min).

Motor task performance was recorded online using a custom-built device that has been described previously in detail (Schaechter et al.

Table 1

Patient and matched control subject characteristics

Patient	Premorbid hand dominance	Stroke-affected hand	Age (years)	Gender	Time poststroke (years)	Acute UL (hand) MRC score	Lesion		Matched control subject		
							Location	Volume (cm ³)	Hand dominance	Age (years)	Gender
1	R	L	52	M	0.5	3	R CR, BG, temporal lobe	15.2	R	58	F
2	R	R	47	M	3.9	0 (0)	L CR, BG, IC, inferior frontal lobe	77.3	R	46	M
3	R	R	41	F	5.9	0-3 (0)	L medial temporal lobe, posterior limb IC	0.9	R	43	F
4	R	R	69	M	1.6	4	L CR, BG, temporal lobe	61.2	R	68	M
5	R	L	76	F	2	1 (0)	R CR, temporal lobe	3.4	R	72	M
6	R	R	62	F	1.2	3-4+ (3+)	L CR	0.7	R	62	F
7	R	L	48	F	1.7	0 (0)	R frontal and parietal lobe white matter	10.1	R	55	M
8	L	R	60	M	5.8	0-3 (0)	L CR, BG	4.2	L	69	M
9	R	R	61	M	2.2	0 (0)	L frontal lobe, parietal lobe	33.8	R	59	M
10	R	L	69	M	1.2	1-3 (1)	R BG	0.7	R	70	M
Summary	9R/1L	6R/4L	59 \pm 11	4F/6M	2.6 \pm 1.9				9R/1L	60 \pm 10	3F/7M

Note: M, male; F, female; R, right; L, left; UL, upper limb; IC, internal capsule; BG, basal ganglia; and CR, corona radiata. UL MRC scores are strength measures (scale 0-5; 0 = no power, 5 = normal) for muscles of the affected upper limb acutely after stroke, as reported in the medical record; hand MRC scores are given in parentheses if available; summary values are mean \pm SD.

2006). The device utilizes microelectromechanical system (MEMS) gyroscopes to measure angular velocity of each of the 10 digits. Use of the finger motion-sensing device during magnetic resonance imaging (MRI) has been shown neither to cause magnetic resonance image artifacts nor alter fMRI statistical activation maps. The angular velocity data were used to compute the mean duration, frequency, amplitude, speed, and acceleration of the 5 digits of the moving hand, as described previously. In addition, mean jerk was computed by applying a low-pass filter (ninth order Butterworth, cutoff frequency = 20 Hz) to the angular velocity time series from each of the digits, taking the second derivative of the filtered time series, then counting the frequency of deflections greater than 5×10^4 degrees/s³. The possibility that digits of the hand contralateral to the task-performing hand moved in a mirroring fashion (i.e., mirror movements) was also examined. Mirror movements were quantified by dividing the mean movement amplitude of the task-performing digits into the mean movement amplitude of the contralateral digits and multiplying by 100. Separate 2-way, mixed model analysis of variance (ANOVA), with group (patients, controls) as the between-subjects factor and task (synergistic and nonsynergistic) as the within-subjects factor, was used to test for main and interaction effects on each kinematic parameter. Alpha was set to 0.05 with no correction for multiple comparisons.

Image Acquisition

Magnetic resonance images were acquired using a 3T Siemens Trio magnetic resonance scanner and a transmitter/receiver Bruker circular polarization head coil. With the subject lying supine on the scanner bed, a custom-formed bite bar was used to limit head motion. The elbows were slightly flexed so that both pronated forearms rested on the lower trunk and thighs. Splints were used to support the wrists at about 20° extension. Straps and cushions were used to stabilize the trunk and arms.

Blood oxygenation level-dependent (BOLD) images were acquired parallel to the intercommissural plane using a T2*-weighted gradient echo, echo planar imaging sequence (repetition time [TR] = 1500 ms; echo time [TE] = 30 ms; flip angle [α] = 90°; field-of-view [FOV] = 200 × 200 mm; matrix size = 64 × 64; slice thickness = 5 mm; interslice gap = 1 mm; number of slices = 23; and acquisitions/slice = 165) equipped with real-time correction for head motion (Thesen et al. 2000). BOLD image collection was preceded by 4 dummy scans to allow for equilibration of the MRI signal.

Two structural volumes were collected for anatomical localization and cortical surface reconstruction using a T1-weighted magnetization prepared rapid gradient echo (MP-RAGE) sequence (TR = 7 ms; TE = 3 ms; α = 7°; FOV = 256 × 256 mm; matrix size = 192 × 256; and effective slice thickness = 1.33 mm). In stroke patients, T2-weighted turbo spin-echo images (TR = 5300 s; TE = 103 ms; α = 180°; FOV = 210 × 210 mm; and matrix size = 256 × 256) were obtained for determination of lesion localization and volume, using the same slice specifications as for the BOLD images.

Image Analysis

To perform group-level image analysis, BOLD and MP-RAGE images from patients with a left hemiparesis and right-sided stroke (patients no. 1, 5, 7, and 10) were flipped about the midsagittal plane, thereby lateralizing the damaged hemisphere to the left in all patients. In addition, BOLD and MP-RAGE images from the matched control subjects of these patients were flipped midsagittally, thereby removing the potential confound of hand used for task performance on between-group differences in activation.

Freesurfer software (<http://surfer.nmr.mgh.harvard.edu>) was used to compute a model of the cortical surface of each subject based on the MP-RAGE images using procedures described in detail previously (Dale et al. 1999; Fischl, Sereno, Dale 1999). Each cortical surface model was spatially normalized to a spherical surface template using an automated procedure that optimally aligns major cortical gyri and sulci (Fischl, Sereno, Tootell, Dale 1999) and then transformed, using SUMA software (<http://afni.nimh.nih.gov/afni/suma>), to a standard cortical surface composed of nodes forming a triangular mesh. All fMRI results are displayed on the group-average standard cortical surface that best accounts for the topological variability of the subjects in this study (Fischl, Sereno,

Tootell, Dale 1999). This surface was generated by averaging the standard cortical surfaces from all study subjects.

Preprocessing and statistical analysis of functional images was performed using AFNI software (<http://afni.nimh.nih.gov/afni>). The functional volumes from each subject were preprocessed by correcting retrospectively for motion, normalizing signal intensity, and coregistering with their structural volume. The BOLD data along the normal vector through the gray/white matter border-pial surface were mapped to the standard cortical surface. The surface-mapped BOLD data were spatially smoothed using a 2-dimensional Gaussian filter (Chung et al. 2003) with a full-width at half-maximum of 6 mm.

Statistical analysis of individual subject data was conducted for each of the motor tasks separately using a general linear model (GLM) fit at each node of the cortical surface. The model included a stimulus input function defined as a boxcar convolved with a canonical hemodynamic response, baseline and linear drift terms, and motion-correction parameters as nuisance regressors. The resultant parameter estimates that reflected BOLD signal changes during movement relative to rest were entered into random effects group analyses. We evaluated group-average activation during performance of each motor task using one sample *t*-tests; within-group differences in activation during performance of the 2 motor tasks using 2-tailed, paired *t*-tests; and between-group differences in activation during performance of each motor task using 2-tailed, unpaired *t*-tests.

We also evaluated for between-group differences in cortical activation changes associated with performance of the nonsynergistic motor task versus the synergistic motor task. This analysis was performed by first concatenating each subject's functional data acquired during the 2 tasks. Then, the GLM described above was applied with the addition of a regressor contrasting the 2 motor tasks (nonsynergistic-synergistic). The resultant parameter estimates that reflected the difference in BOLD signal change between the 2 motor tasks in each patient and control were entered into a random effects 2-tailed, unpaired *t*-test.

Statistical activation maps were corrected for multiple comparisons by controlling for false positives using a combination of individual node-level probability and minimum cluster-size threshold (Forman et al. 1995). Based on Monte Carlo simulations (10 000 iterations) performed on synthesized white Gaussian noise data that was resampled onto our group-average cortical surface and smoothed, we determined that with the individual node probability set to 0.05, an activation cluster with a surface area of ≥ 323 mm² controlled the false-positive rate to 0.05, whereas an activation cluster with a surface area of ≥ 463 mm² controlled the false-positive rate to 0.01. With the individual node probability set to 0.01, an activation cluster with a surface area of ≥ 234 mm² controlled the false-positive rate to 0.01.

For localization of activation clusters, the standard cortical surface from each subject was labeled using an automated probabilistic, surface-based parcellation method (Fischl et al. 2004). All activation clusters were found to be composed of more than one neighboring cortical gyrus and sulcus. We computed the percentage of each activation cluster residing in component gyri and sulci, based on surface area, in each subject. Mean percentages (\pm standard deviation [SD]) across the subjects of each component gyrus and sulcus within an activation cluster are reported. To prevent anatomical misattribution of an activation cluster, a particular gyrus or sulcus was considered to be part of the cluster only if it contributed greater than 5% to the total surface area of the cluster across the subjects.

Functional assignments were made to selected activation clusters. An activation cluster that included the postcentral gyrus, postcentral sulcus, central sulcus, and precentral gyrus was identified as the primary somatosensory cortex and primary motor cortex (S1/M1) (Geyer et al. 1996, 1999; Grefkes et al. 2001). An activation cluster that included the superior frontal and paracentral gyri and resided posterior to the level of the genu of the corpus callosum was identified as the supplementary motor area (SMA) (Fink et al. 1997). An activation cluster that included the inferior aspect of the precentral gyrus and sulcus, opercular part of the inferior frontal gyrus, and inferior frontal sulcus was identified as the ventral premotor cortex (PMv) (Tomaiuolo et al. 1999; Binkofski and Buccino 2006).

We examined whether the activation in clusters exhibiting significant between-group differences during the synergistic and nonsynergistic

motor tasks (see Results) related to the degree of residual hand motor impairment in the patients. For each of these activation clusters localized on the standard cortical surface, the mean BOLD signal change elicited by the appropriate motor task was computed for each patient. Pearson's correlation coefficient was used to evaluate, for each of these clusters, the relationship between activation (mean BOLD signal change, in percent) in the patients and 1) overall hand motor function (first principal component of behavioral scores) and 2) each movement parameter measured during fMRI. The significance of a correlation was determined using a *z*-test following Fisher's *r* to *z* transformation, with alpha set to 0.05.

Lesion volume was determined by an experienced neuroradiologist who manually outlined the T2 abnormality slice by slice using Alice software (Hayden Image Processing Solutions, Denver, CO).

Results

Hand Motor Function

Using measures of index finger tapping speed and fine manual dexterity (Purdue Pegboard test), the mean level of motor function of the affected hand of the chronic stroke patients was about 75% of their unaffected hand (Table 2). Although this level of hand motor function indicates that the patients had relatively good motor recovery, they still showed residual hand motor impairments compared with the normal control subjects. Normalized speed of tapping the stroke-affected index finger of patients was significantly reduced relative to the comparable finger of controls (patients: $74.6 \pm 25.4\%$; controls: $100.5 \pm 8.7\%$; $P < 0.01$, unpaired *t*-test). Normalized performance on the Purdue Pegboard test of the stroke-affected hand of patients was significantly impaired (patients: $76.5 \pm 26.0\%$; controls: $95.7 \pm 9.8\%$; $P < 0.05$, unpaired *t*-test). The first principal component of the hand motor function scores from all of the patients accounted for 88.5% of the variability and was taken to reflect overall hand motor function of each patient.

Motor Task Performance during fMRI

Figure 1 shows angular velocity time series from a representative control subject during performance of the synergistic and nonsynergistic motor tasks during fMRI. Analysis of the angular velocity data acquired online from the subjects during the 2 motor tasks revealed no significant main effect of group on the duration, frequency, speed, acceleration, jerk, or mirroring (each $P > 0.05$, mixed model ANOVA; Table 3). We did detect a significant ($P = 0.041$) main effect of group on the amplitude of digit movement, with the patients moving the digits approximately 94% the range of motion of that done by the controls. There was no significant main effect of task on any movement parameter, indicating that the 2 motor tasks were matched kinematically, as intended. Further, there was no significant interaction effect of task and group on any movement parameter.

fMRI Results

In the control subjects and stroke patients, performance of the synergistic or nonsynergistic motor task activated a similar network of cortical areas (Fig. 2). In both subject groups, performance of either motor task activated the contralateral (ipsilesional in patients) sensorimotor cortex, including the hand region of the precentral and postcentral gyri/sulci, contralateral posterior parietal cortex, ipsilateral (contralesional in patients) precentral gyrus/sulcus, bilateral SMA/cingulate, and bilateral parietal operculum. Examination of the difference in activation during the 2 motor tasks (nonsynergistic-synergistic) in the control sub-

Table 2

Motor function of the stroke-affected hand of patients

Patient	Motor function test		Overall hand motor function (first principal component)
	Index finger tapping (% unaffected hand)	Purdue pegboard (% unaffected hand)	
1	79.8	82.3	7.80
2	34.1	39.4	-54.81
3	107.1	97.7	37.86
4	91.3	112.4	37.42
5	58.2	52.8	-28.42
6	59.3	88.0	-2.37
7	98.8	92.5	28.35
8	85.3	50.8	-10.99
9	93.3	100.0	29.90
10	39.2	48.5	-44.73
Mean \pm SD	74.6 \pm 25.4	76.4 \pm 26.0	

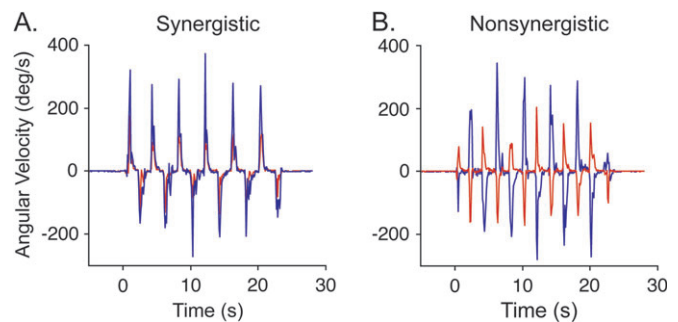


Figure 1. Angular velocity time series of digit movement acquired during fMRI from a representative control subject. Measurements of the thumb (red) and middle finger (blue) during a movement epoch are shown. (A) Time series of the synergistic hand motor task showing the digits moving in unison. (B) Time series of the nonsynergistic hand motor task showing the thumb and middle finger moving in opposite directions.

jects revealed significantly increased activation in the contralateral postcentral gyrus/sulcus extending into the supramarginal part of the inferior parietal cortex ($P < 0.05$, corrected, paired *t*-test), ipsilateral postcentral gyrus/sulcus extending into the anterior part of the intraparietal sulcus ($P < 0.05$), and the ipsilateral central sulcus, precentral gyrus/sulcus ($P < 0.01$). In a separate cohort of healthy normal subjects, performance of the nonsynergistic task was perceived as more challenging than the synergistic task, evaluated using a visual analogue scale ($P < 0.05$, 2-tailed paired *t*-test; see Supplementary Material). In the patients, the increase in task challenge resulted in significantly increased activation in the ipsilesional postcentral gyrus/sulcus, angular part of the inferior parietal cortex and intraparietal sulcus ($P < 0.01$), and the contralesional postcentral gyrus/sulcus, angular part of the inferior parietal cortex, superior parietal cortex, and intraparietal sulcus ($P < 0.01$), central sulcus, precentral gyrus/sulcus ($P < 0.01$), and occipitotemporal cortex ($P < 0.01$). There were no cortical areas with significant decreases in activation during performance of the nonsynergistic motor task relative to the synergistic motor task in either the control or patient group.

We tested for differences in cortical activation between the stroke patients and control subjects during performance of each of the motor tasks ($\text{synergistic}_{\text{patients}} - \text{synergistic}_{\text{controls}}$; $\text{nonsynergistic}_{\text{patients}} - \text{nonsynergistic}_{\text{controls}}$). Activation during performance of the synergistic motor task was significantly increased in the patients relative to controls in the contralesional

Table 3

Motor performance during fMRI

Movement parameter	Synergistic motor task		Nonsynergistic motor task	
	Patients	Controls	Patients	Controls
Duration (s)	22.5 ± 0.7	22.2 ± 0.2	22.8 ± 0.4	22.3 ± 0.2
Frequency (Hz)	0.25 ± 0.00	0.25 ± 0.00	0.25 ± 0.00	0.25 ± 0.00
Amplitude (% max range of motion)*	78.2 ± 9.1	85.2 ± 5.0	81.1 ± 4.8	84.5 ± 4.6
Speed (deg/s)	75.5 ± 16.2	74.8 ± 14.0	73.5 ± 19.8	83.3 ± 11.2
Acceleration/10 ² (deg/s ²)	15.2 ± 5.4	13.2 ± 2.5	13.7 ± 5.7	13.0 ± 4.0
Jerk/10 ³ (counts > 5 × 10 ⁴ deg/s ³)	18.8 ± 11.5	17.3 ± 5.4	19.8 ± 7.9	18.8 ± 5.7
Mirror movements (% amplitude of moving digits)	0.12 ± 0.80	-0.04 ± 0.41	-0.02 ± 0.62	0.08 ± 0.45

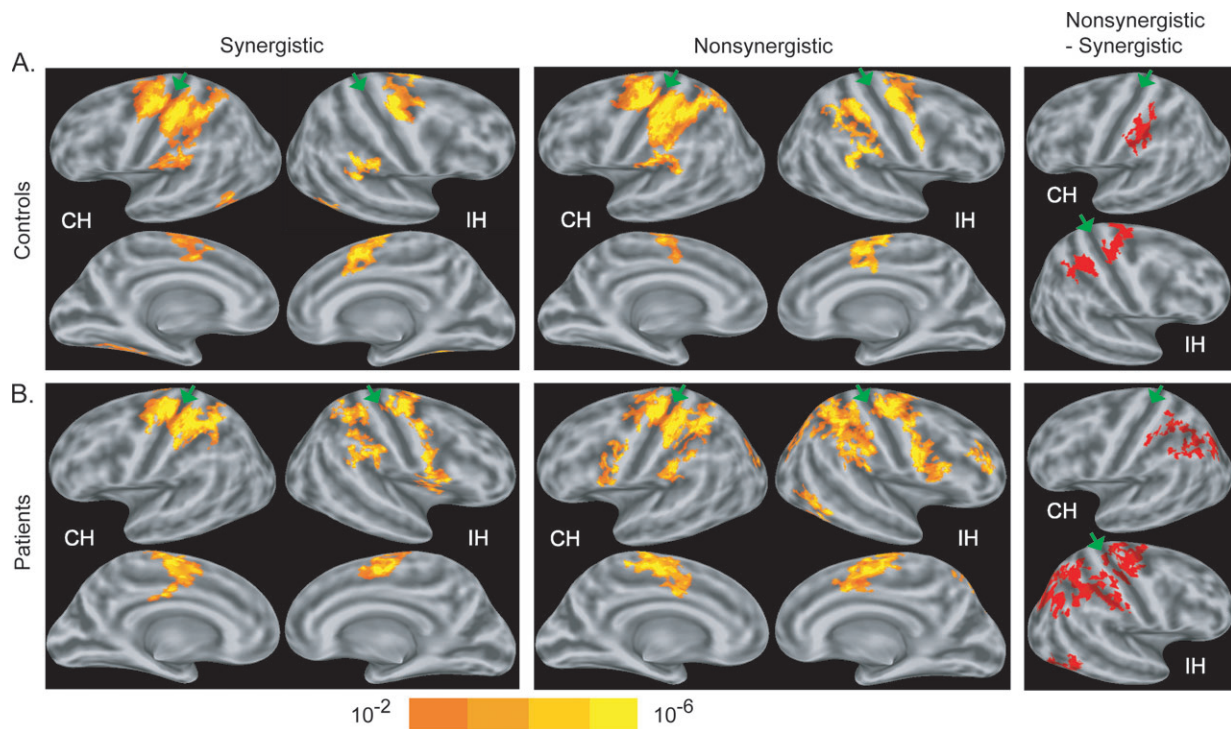
* $P < 0.05$ main effect of group, mixed model ANOVA; values are mean ± SD.

Figure 2. Functional MRI results showing cortical activation in normal control subjects (A) and chronic stroke patients (B) during unilateral performance of synergistic and nonsynergistic motor tasks and the differences in activation between the 2 tasks. First and second columns: Group-average statistical maps of activation during performance of each of the motor tasks ($P < 0.01$, corrected, 1-sample t -test). First row are lateral surfaces of the hemispheres; second row are medial surfaces of the hemispheres. CH = contralateral (ipsilateral in patients) hemisphere. IH = ipsilateral (contralesional in patients) hemisphere. Third column: clusters of significantly increased activation during performance of the nonsynergistic relative to the synergistic motor task ($P < 0.05$, corrected, paired t -test). Maps are overlaid on a model of the group-average, inflated cortical surface. Dark gray regions are the fundus of a sulcus; light gray regions are the crowns of a gyrus. Green arrowheads point to central sulcus.

S1/M1 ($P < 0.01$, corrected, unpaired t -test; Fig. 3A and Table 4, A). During performance of the nonsynergistic motor task, the patients showed significantly increased activation, relative to controls, not only in the contralesional S1/M1 ($P < 0.05$, corrected, unpaired t -test) but also in the contralesional PMv ($P < 0.01$), SMA/cingulate ($P < 0.05$), and occipitoparietal cortex ($P < 0.01$) (Fig. 3B and Table 4, B). There were no cortical areas that exhibited significant decreases in activation in the patients relative to controls during the synergistic or nonsynergistic motor task.

We also tested for between-group differences in cortical activation change associated with performance of the nonsynergistic motor task versus the synergistic motor task ([nonsynergistic - synergistic]_{patients} - [nonsynergistic - synergistic]_{controls}). This contrast revealed a cluster in the contralesional occipitoparietal

cortex ($P < 0.01$, corrected, unpaired t -test; Fig. 3C and Table 4, C). This cluster was located largely in the posterior aspect of the intraparietal sulcus and had extensions into the extrastriate cortex, angular part of the inferior parietal gyrus, and superior parietal gyrus. This result indicates that the increase in motor skill challenge elicited a significantly greater enhancement in activation in the contralesional occipitoparietal cortex of the patients compared with controls.

We questioned whether the observed increases in cortical activation in the contralesional hemisphere of the patients, relative to controls, were related to the degree of residual motor impairment of the stroke-affected hand. To address this question, we performed correlation analyses between overall hand motor function (first principal component of the behavioral measures) and activation (mean BOLD signal change) in the patients

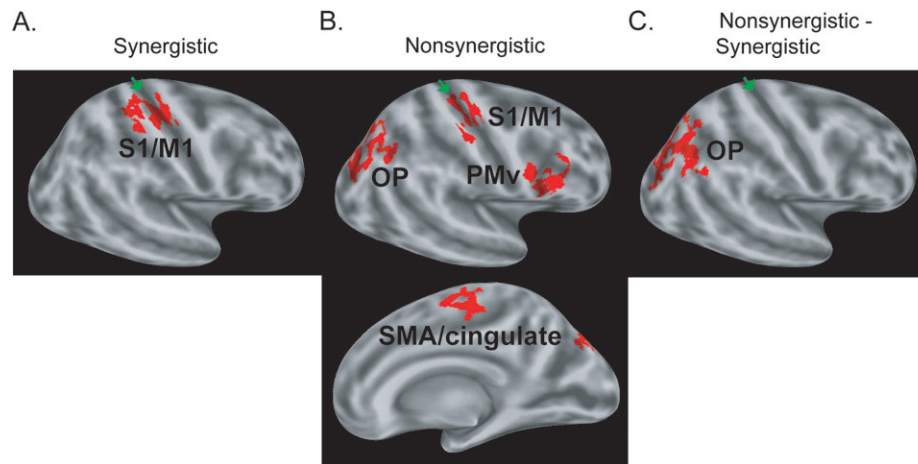


Figure 3. Functional MRI results showing differences in cortical activation in chronic stroke patients compared with normal control subjects during performance of the hand motor tasks. (A) Between-group differences in activation during the synergistic motor task. Patients showed a significant ($P < 0.01$, corrected, unpaired t -test) increase in activation in the contralateral S1/M1. (B) Between-group differences in activation during the nonsynergistic motor task. Patients showed significant increases in activation in the contralateral S1/M1 ($P < 0.05$, corrected, unpaired t -test), PMv ($P < 0.01$), occipitoparietal cortex (OP; $P < 0.01$), and SMA/cingulate ($P < 0.05$). (C) Between-group differences in cortical activation changes associated with performance of the nonsynergistic motor task versus the synergistic motor task. Patients showed a significant task-dependent increase in activation in the contralateral OP ($P < 0.01$, corrected, unpaired t -test) relative to that in controls.

Composite cortical area of cluster	Anatomical areas within cluster (% surface area of cluster, mean \pm SD)	Cluster size (mm ²)	Cluster-level significance (P)
A. Synergistic motor task Contralateral M1/S1	Central sulcus (42 \pm 5%); Postcentral gyrus (31 \pm 5%); Precentral gyrus (14 \pm 4%); Postcentral sulcus (13 \pm 7%)	506	0.01
B. Nonsynergistic motor task Contralateral occipitoparietal cortex	Intraparietal sulcus (54 \pm 5%); Superior occipital sulcus (18 \pm 5%); Superior occipital gyrus (12 \pm 2%); Inferior parietal gyrus, angular part (8 \pm 4%);	943	0.01
Contralateral PMv	Precentral sulcus, inferior part (54 \pm 5%); Frontal inferior sulcus (20 \pm 4%); Frontal inferior gyrus, opercular part (14 \pm 4%); Precentral gyrus (9 \pm 4%);	515	0.01
Contralateral SMA/cingulate	Superior frontal gyrus (56 \pm 12%); Paracentral gyrus, (20 \pm 8%); Cingulate sulcus, main part (19 \pm 5%)	378	0.05
Contralateral M1/S1	Central sulcus (52 \pm 6%); Postcentral gyrus (18 \pm 4%); Precentral gyrus (30 \pm 6%)	328	0.05
C. Nonsynergistic-synergistic motor task Contralateral occipitoparietal cortex	Intraparietal sulcus (55 \pm 6%); Superior occipital sulcus (17 \pm 4%); Inferior parietal gyrus, angular part (16 \pm 5%); Superior occipital gyrus (6 \pm 1%); Superior parietal gyrus (6 \pm 4%)	1080	0.01

in the: 1) contralateral S1/M1 cluster identified as showing a between-group difference during the synergistic motor task and 2) contralateral S1/M1, PMv, SMA/cingulate, and occipitoparietal cortex clusters identified as showing a between-group difference during the nonsynergistic motor task. We also performed correlation analyses between each movement parameter measured during fMRI (duration, frequency, amplitude, speed, acceleration, jerk, and mirroring) and activation in the patients in these 2 sets of activation clusters. No significant correlations were revealed (each $P > 0.05$, z -test; data not shown). These results exclude residual motor impairment of the stroke-affected hand as accounting for the increased cortical activation we observed in the contralateral hemisphere of the patients.

Discussion

The aim of this study was to gain insight into the cortical processes involved in the restoration of motor skill after hemiparetic stroke. During fMRI, chronic stroke patients with good

motor recovery and normal control subjects performed 2 motor tasks that represent the evolution of motor recovery after hemiparetic stroke: a synergistic motor task (the 5 digits flexed and extended in unison) and a nonsynergistic motor task (the thumb flexed while the other four digits extended, and visa versa). As the nonsynergistic task involved independent movement of the thumb relative to the other digits, this task required more motor skill than the synergistic task. The 2 motor tasks were matched kinematically and were performed nearly equally well by the stroke-affected hand of patients and comparable hand of controls, allowing us to make meaningful comparisons in activation relative to an increment in motor skill challenge. The main finding was that the stroke patients exhibited enhanced activation in contralateral motor task-related cortices during affected hand movement, relative to that in controls, as a function of motor skill challenge. Performance of the synergistic motor task increased activation in the patients relative to controls in the contralateral S1/M1. Performance of the nonsynergistic motor task increased activation in the patients relative to controls not

only in the contralesional S1/M1 but also in the contralesional PMv, SMA/cingulate, and occipitoparietal cortex. We also observed that activation in the contralesional occipitoparietal cortex was differentially elevated in the patients relative to controls with the increase in motor skill challenge, suggesting particular importance of this cortical area to restored performance of dexterous, skilful movement after hemiparetic stroke.

Effect of Motor Skill Challenge on Cortical Activation in Patients and Controls

Increasing the motor skill challenge to the normal control subjects and relatively well-recovered stroke patients, by having them perform the nonsynergistic motor task compared with the synergistic motor task, enhanced activation in postcentral gyrus/sulcus bilaterally (extending into the posterior parietal cortex differentially in the 2 subject groups) and the ipsilateral (contralesional in patients) central sulcus, precentral gyrus/sulcus. An fMRI study by Ehrsson et al. (2002), which had normal healthy adults perform the same synergistic and nonsynergistic motor tasks as used in the current study also found increased activation in bilateral postcentral sulcus and ipsilateral precentral gyrus/sulcus during performance of the skilled task versus unskilled task. However, we did not replicate their observation of increased activation in the contralateral (ipsilesional) premotor cortex or SMA/cingulate associated with the increase in motor task challenge in either subject group. Further, we found increased activation in the anterior portion of the ipsilateral (contralesional) central sulcus, where M1 resides, in both subject groups. The reason for these differences is not known. One possibility is that they relate to differences between the 2 studies in the average age of the subjects (60 vs. 27 years). Age-related differences in motor task-related activation have been reported in the contralateral premotor cortex, SMA, cingulate, and ipsilateral M1 in normal healthy adults (Mattay et al. 2002; Ward and Frackowiak 2003), leading to the possibility that these cortices in the older adults of our study responded differentially to the motor skill challenge compared with those in the younger adults of the Ehrsson study.

Increasing motor skill challenge has been shown previously to enhance recruitment within a bilateral frontoparietal cortical network in normal healthy adults (Hamzei et al. 2002; Mayville et al. 2002; Oullier et al. 2005). The observed activation increases in bilateral parietal cortex (postcentral gyri/sulci extending into posterior parietal cortices) in the controls and patients during the nonsynergistic versus synergistic motor task may indicate increased cortical processing related to the planning and somatosensory guidance of coordinated digit movement (Hikosaka et al. 1985; Brochier et al. 1999; Gardner et al. 1999). The enhanced activation in the ipsilateral (contralesional) frontal cortices (precentral gyrus/sulcus and central sulcus) with increased motor task challenge may relate to a role that the ipsilateral primary and premotor motor cortices play in the execution of complex digit movements (Rao et al. 1993; Shibasaki et al. 1993; Sadato et al. 1996; Chen et al. 1997; Verstynen et al. 2005; Carey et al. 2006).

Effect of Motor Skill Challenge on Cortical Activation in Patients Relative to Controls

The stroke patients showed enhanced activation in motor task-related cortices of the contralesional hemisphere during performance of the synergistic and nonsynergistic motor tasks relative

to that in controls. Analysis of the finger motion data acquired during fMRI revealed no significant differences in the duration, frequency, speed, acceleration, or jerk of the motor tasks performed by the stroke-affected hand of patients versus the comparable hand of controls. We did find a small, but significant, decrease in movement amplitude in the patients, to approximately 94% of that in controls. A prior study in normal healthy adults reported that increasing the amplitude of finger movement was associated with increased activation in contralateral motor task-related cortices, with no observed change in activation in ipsilateral motor task-related cortices (Waldvogel et al. 1999). Accordingly, it is rather unlikely that the increased activation we found in the contralesional motor task-related cortices in the patients was due to their reduced amplitude of finger movement. Further, in the patients, we found no significant correlation between any measured movement parameter and activation in the contralesional motor task-related cortices exhibiting between-group differences. Overall, then, our results indicate that the between-group differences in activation observed in the contralesional motor task-related cortices were not likely due to differences in motor task performance during fMRI.

Voluntary movement of the affected hand of stroke patients can elicit involuntary mirror movements of the unaffected hand (Nelles et al. 1998). Such mirroring may contribute to increased activation in contralesional motor task-related cortices in stroke patients during fMRI (Wittenberg et al. 2000). However, analysis of the finger motion data acquired during fMRI revealed no significant differences between the patients and controls in mirror movements of the “resting” hand during voluntary motor task performance. This result indicates that the enhanced activation in the contralesional motor task-related cortices in the patients relative to controls was not accounted for by an increased occurrence of mirror movements in the patients. Our result is concordant with the findings of Butefisch et al. (2005) who demonstrated activation in the contralesional M1 and premotor cortex of well-recovered stroke patients during affected hand movement that was not accompanied by covert mirror movements assessed by electromyography during fMRI.

Increased activity in contralesional motor cortices of stroke patients has been suggested by some to relate to poor motor outcome (Turton et al. 1996; Netz et al. 1997; Ward et al. 2003b). However, our patients had relatively good motor outcomes, with the mean level of motor function of the stroke-affected hand across the group about 75% of the unaffected hand and approximately half the group exhibiting near-normal hand motor function. Further, during fMRI, only the slight reduction in movement amplitude in the patients relative to controls indicated a residual motor performance deficit. Moreover, we found no significant correlation (negative or positive) between the magnitude of activation in the contralesional cortices (S1/M1, PMv, SMA/cingulate, and occipitoparietal cortex) during affected hand task performance and movement amplitude (or any other movement parameter measured during fMRI) or overall hand motor function in the patients. Together, these observations indicate that the enhanced activation in the contralesional motor task-related cortices was not related to the level of residual hand motor impairment in the patients.

On the surface, our result of increased activation in the contralesional S1/M1 during performance of the synergistic motor task in the chronic stroke patients differs from that of Ward et al. (2003a, 2003b) who reported that brain activation during

performance of a hand gripping task, also a synergistic motor task, was not different in well-recovered chronic stroke patients from that in normal controls. However, the 2 synergistic tasks differ with regard to motor challenge. The synergistic task employed by Ward et al. involved a palmar grasp, which is the one of the earliest motor functions to reappear after hemiparetic stroke (Twitchell 1951; Brunnstrom 1966). In contrast, our synergistic task was digit flexion and extension through the full range of motion; this task involves grasp and release functions of the digits and recovers later after hemiparetic stroke (Twitchell 1951; Brunnstrom 1966). Accordingly, our observation of enhanced contralesional S1/M1 activation during performance of a synergistic motor task in well-recovered stroke patients likely reflects increased task demands relative to that in controls.

Our observation that increasing the motor skill challenge enhanced activation within an extended cortical network of the contralesional hemisphere in stroke patients relative to that in controls has similarities and dissimilarities with the few other studies that employed motor tasks of varying skill challenge in stroke patients. Similar to our findings, those of Cramer et al. (2001) and Foltys et al. (2003) in well-recovered stroke patients reported that a motor task requiring increased skill was associated with enhanced activation in the contralesional M1. In contrast, Nair et al. (2007) recently reported that well-recovered stroke patients showed enhanced activation in the ipsilesional S1/M1 during a skilled motor task (index finger adduction/abduction), whereas they showed enhanced activation in bilateral S1/M1 during performance of a relatively unskilled motor task (wrist flexion/extension). These later observations are difficult to reconcile with our findings and those of the previous studies described. As Nair et al. discuss, because they did not monitor motor performance during fMRI, it is possible that performance differences in the patients relative to controls confounded their activation results. Moreover, the current study is the first to employ kinematically matched motor tasks, allowing us to make meaningful, direct comparisons in activation related to an increment in motor skill challenge.

The observed increase in contralesional M1 activation in the patients during performance of the synergistic and nonsynergistic motor tasks could reflect changes in its interaction with ipsilesional M1. In normal healthy adults, performance of unimanual motor tasks with increasing challenge (e.g., sequence length, coordination, force precision, and accuracy) has been shown to enhance activity in ipsilateral motor task-related cortices, including M1 (Catalan et al. 1998; Ehrsson et al. 2000; Hummel et al. 2003; Verstynen et al. 2005; Carey et al. 2006). Interfering with activity in the ipsilateral M1, by means of transcranial magnetic stimulation (TMS), has been shown to disrupt the timing of behavioral performance (Chen et al. 1997) and alter the timing of muscle recruitment (Davare et al. 2006) of complex hand movements in normal healthy adults. These studies have suggested that the ipsilateral M1 is normally involved in meeting the spatiotemporal demands placed on the contralateral M1 to execute complex hand movements, possibly via transcallosal connections. By extension, in patients who have made good motor recovery after hemiparetic stroke, the ipsilesional M1 may rely more heavily on the contralesional M1 to control spatiotemporal aspects of affected hand movement. This hypothesis is supported by the recent demonstration in well-recovered chronic stroke patients that TMS-induced suppression of the contralesional M1 impaired the timing of a complex movement performed by the affected hand (Lotze et al.

2006). However, other studies found that a similar experimental manipulation to the contralesional M1 improved (Mansur et al. 2005; Takeuchi et al. 2005) or did not change (Johansen-Berg et al. 2002; Werhahn et al. 2003) motor function of the stroke-affected hand. The reason for these inconsistent results from studies using TMS is not clear. Nonetheless, our fMRI results are consistent with the implications from studies in normal healthy adults and suggest that enhanced activation in the contralesional M1 in well-recovered chronic stroke patients may reflect this area's participation in the neural control of motor tasks performed by the affected hand. The joint increase in activation in the contralesional S1 in our patients may reflect its communication with the contralesional M1 as these 2 neighboring cortical areas have tight anatomical (Jones 1985; Cauller et al. 1998) and functional (Hikosaka et al. 1985; Brochier et al. 1999) connections.

Performance of the skilled nonsynergistic motor task by the chronic stroke patients enhanced activation relative to that in controls in the contralesional S1/M1, as well as in other frontal motor cortices of the contralesional hemisphere (PMv, SMA/cingulate). The enhanced activation in additional contralesional frontal motor cortices in the patients may reflect utilization of further processes to successfully perform an incrementally more challenging motor task. Bilateral PMv has been shown to be a cortical area critical to linking observation of visual cues to execution of hand actions in normal healthy adults (Jacoboni et al. 1999; Nishitani and Hari 2000; Buccino et al. 2001; Koski et al. 2002). The enhanced activation we observed in the contralesional PMv in the patients during the nonsynergistic motor task may reflect greater utilization of this observation-execution matching system. In monkeys with good motor recovery after an experimentally-induced lesion to M1, neural activity just prior to movement of the affected digits has been observed to increase in the SMA bilaterally, as compared with before the lesion (Aizawa et al. 1991). Accordingly, it is reasonable that the enhanced activation we observed in the patients in the contralesional SMA, with extension into the neighboring cingulate cortex, during the nonsynergistic motor task might have been involved in planning the more challenging motor task.

Activation in the contralesional occipitoparietal cortex increased during performance of the skilled nonsynergistic motor task, along with that in the contralesional frontal motor cortices, in the patients relative to controls. Notably, we also found that the increase in motor skill challenge (nonsynergistic vs. synergistic task) elicited a significantly greater enhancement in activation in the contralesional occipitoparietal cortex of the patients compared with that of controls. A recent study in well-recovered chronic stroke patients found that interfering with activity (by means of TMS) in contralesional frontal motor cortices (M1, dorsal premotor cortex) disrupted the timing of a complex (i.e., nonsynergistic) hand movement, whereas interfering with activity in the contralesional superior parietal cortex disrupted the accuracy as well as the timing of the complex hand movement (Lotze et al. 2006). These findings, together with our current results, suggest that the contralesional occipitoparietal cortex may play a particularly important role in the restoration of dexterous, skilful movement of the affected hand of stroke patients beyond that played by the contralesional frontal motor cortices. The occipitoparietal cortex, and specifically the posterior aspect of the intraparietal sulcus where the largest fraction of activation in this area resided, is known to be involved in motor coordination (Ramnani et al. 2001; Ehrsson

et al. 2003), visual guidance of movement (Culham and Valyear 2006), and attention (Mesulam 1990; Nobre et al. 1997; Gitelman et al. 1999) in normal healthy adults. Stroke patients with good motor recovery may strongly recruit the contralesional, posterior aspect of the intraparietal sulcus to support these processes for successful performance of skilful motor tasks by their affected hand.

In conclusion, the current study found that activation in the contralesional cortical network was modulated by the level of motor skill challenge to the affected hand of chronic stroke patients with good motor recovery. These findings suggest that successful recovery of motor skill after hemiparetic stroke involves participation of the contralesional cortical network.

Supplementary Material

Supplementary material can be found at: <http://www.cercor.oxfordjournals.org/>.

Funding

National Institutes of Health (NIH)–National Institute of Child Health and Human Development (K23-HD044425); NIH–National Center for Research Resources (P41-RR14075); Mental Illness and Neuroscience Discovery Institute.

Notes

We thank Mingwang Zhu for calculating lesion volumes, Mark Vangel for statistical advice, and Brendan Connell for help in data acquisition and preliminary analysis. *Conflict of Interest:* None declared.

Address correspondence to Judith D. Schaechter, PhD, MGH/MIT/HMS Athinoula A. Martinos Center for Biomedical Imaging, Room 2301, Building 149, 13th Street, Charlestown, MA 02129, USA. Email: judith@nmr.mgh.harvard.edu.

References

Aizawa H, Inase H, Shima K, Tanji J. 1991. Reorganization of activity in the supplementary motor area associated with motor learning and functional recovery. *Exp Brain Res.* 84:668–671.

Binkofski F, Buccino G. 2006. The role of ventral premotor cortex in action execution and action understanding. *J Physiol Paris.* 99:396–405.

Brochier T, Boudreau MJ, Pare M, Smith AM. 1999. The effects of muscimol inactivation of small regions of motor and somatosensory cortex on independent finger movements and force control in the precision grip. *Exp Brain Res.* 128:31–40.

Brunnstrom S. 1966. Motor testing procedures in hemiplegia: based on sequential recovery stages. *Phys Ther.* 46:357–375.

Buccino G, Binkofski F, Fink GR, Fadiga L, Fogassi L, Gallese V, Seitz RJ, Zilles K, Rizzolatti G, Freund HJ. 2001. Action observation activates premotor and parietal areas in a somatotopic manner: an fMRI study. *Eur J Neurosci.* 13:400–404.

Butefisch CM, Kleiser R, Korber B, Muller K, Wittsack HJ, Homberg V, Seitz RJ. 2005. Recruitment of contralesional motor cortex in stroke patients with recovery of hand function. *Neurology.* 64:1067–1069.

Cao Y, D’Olhaberriague L, Vikingstad EM, Levine SR, Welch KMA. 1998. Pilot study of functional MRI to assess cerebral activation of motor function after poststroke hemiparesis. *Stroke.* 29:112–122.

Carey JR, Greer KR, Grunewald TK, Steele JL, Wiemiller JW, Bhatt E, Nagpal A, Lungu O, Auerbach EJ. 2006. Primary motor area activation during precision-demanding versus simple finger movement. *Neurorehabil Neural Repair.* 20:361–370.

Catalan MJ, Honda M, Weeks RA, Cohen LG, Hallett M. 1998. The functional neuroanatomy of simple and complex sequential finger movements: a PET study. *Brain.* 121:253–264.

Caulier LJ, Clancy B, Connors BW. 1998. Backward cortical projections to primary somatosensory cortex in rats extend long horizontal axons in layer I. *J Comp Neurol.* 390:297–310.

Chen R, Gerloff C, Hallett M, Cohen LG. 1997. Involvement of the ipsilateral motor cortex in finger movements of different complexities. *Ann Neurol.* 41:247–254.

Chollet F, DiPiero V, Wise RJS, Brooks DJ, Dolan RJ, Frackowiak RSJ. 1991. The functional anatomy of motor recovery after stroke in humans: a study with positron emission tomography. *Ann Neurol.* 29:63–71.

Chung MK, Worsley KJ, Robbins S, Paus T, Taylor J, Giedd JN, Rapoport JL, Evans AC. 2003. Deformation-based surface morphometry applied to gray matter deformation. *Neuroimage.* 18:198–213.

Cramer SC, Nelles G, Benson RR, Kaplan JD, Parker RA, Kwong KK, Kennedy DN, Finklestein SP, Rosen BR. 1997. A functional MRI study of subjects recovered from hemiparetic stroke. *Stroke.* 28:2518–2527.

Cramer SC, Nelles G, Schaechter JD, Kaplan JD, Finklestein SP, Rosen BR. 2001. A functional MRI study of three motor tasks in the evaluation of stroke recovery. *Neurorehabil Neural Repair.* 15:1–8.

Culham JC, Valyear KF. 2006. Human parietal cortex in action. *Curr Opin Neurobiol.* 16:205–212.

Dale A, Fischl B, Sereno M. 1999. Cortical surface-based analysis. I: segmentation and surface reconstruction. *Neuroimage.* 9:179–194.

Dassonville P, Zhu XH, Urbil K, Kim SG, Ashe J. 1997. Functional activation in motor cortex reflects the direction and the degree of handedness. *Proc Natl Acad Sci USA.* 94:14015–14018.

Davare M, Duque J, Vandermeeren Y, Thonnard JL, Olivier E. 2006. Role of the ipsilateral primary motor cortex in controlling the timing of hand muscle recruitment. *Cereb Cortex.* 17:353–362.

Desrosiers J, Hebert R, Bravo G, Dutil E. 1995. The Purdue pegboard test: normative data for people aged 60 and over. *Disabil Rehabil.* 17:217–224.

Ehrsson HH, Fagergren A, Johansson RS, Forssberg H. 2003. Evidence for the involvement of the posterior parietal cortex in coordination of fingertip forces for grasp stability in manipulation. *J Neurophysiol.* 90:2978–2986.

Ehrsson HH, Fagergren A, Jonsson T, Westling G, Johansson RS, Forssberg H. 2000. Cortical activity in precision- versus power-grip tasks: an fMRI study. *J Neurophysiol.* 83:528–536.

Ehrsson HH, Kuhtz-Buschbeck JP, Forssberg H. 2002. Brain regions controlling nonsynergistic versus synergistic movement of the digits: a functional magnetic resonance imaging study. *J Neurosci.* 22:5074–5080.

Fink GR, Frackowiak RS, Pietrzyk U, Passingham RE. 1997. Multiple nonprimary motor areas in the human cortex. *J Neurophysiol.* 77:2164–2174.

Fischl B, Sereno MI, Dale AM. 1999. Cortical surface-based analysis. II: inflation, flattening, and a surface-based coordinate system. *Neuroimage.* 9:195–207.

Fischl B, Sereno MI, Tootell RBH, Dale AM. 1999. High-resolution intersubject averaging and a coordinate system for the cortical surface. *Hum Brain Mapp.* 8:272–284.

Fischl B, van der Kouwe A, Destrieux C, Halgren E, Segonne F, Salat DH, Busa E, Seidman LJ, Goldstein J, Kennedy D, et al. 2004. Automatically parcellating the human cerebral cortex. *Cereb Cortex.* 14:11–22.

Foltys H, Krings T, Meister IG, Sparing R, Boroojerdi B, Thron A, Topper R. 2003. Motor representation in patients rapidly recovering after stroke: a functional magnetic resonance imaging and transcranial magnetic stimulation study. *Clin Neurophysiol.* 114:2404–2415.

Forman SD, Cohen JD, Fitzgerald M, Eddy WF, Mintum MA, Noll DC. 1995. Improved assessment of significant activation in functional magnetic resonance imaging (fMRI): use of a cluster-size threshold. *Magn Reson Med.* 33:636–647.

Gardner EP, Ro JY, Debowy D, Ghosh S. 1999. Facilitation of neuronal activity in somatosensory and posterior parietal cortex during prehension. *Exp Brain Res.* 127:329–354.

Gerloff C, Bushara K, Sailer A, Wassermann EM, Chen R, Matsuoka T, Waldvogel D, Wittenberg GF, Ishii K, Cohen LG, et al. 2006. Multimodal imaging of brain reorganization in motor areas of the contralesional hemisphere of well recovered patients after capsular stroke. *Brain.* 129:791–808.

Geyer S, Ledberg A, Schleicher A, Kinomura S, Schormann T, Burgel U, Klingberg T, Larsson J, Zilles K, Roland PE. 1996. Two different areas within the primary motor cortex of man. *Nature.* 382:805–807.

- Geyer S, Schleicher A, Zilles K. 1999. Areas 3a, 3b, and 1 of human primary somatosensory cortex. 2. Spatial normalization to standard anatomical space. *Neuroimage*. 11:684-696.
- Gitelman DR, Nobre AC, Parrish TB, LaBar KS, Kim YH, Meyer JR, Mesulam M. 1999. A large-scale distributed network for covert spatial attention: further anatomical delineation based on stringent behavioural and cognitive controls. *Brain*. 122:1093-1106.
- Gorbet DJ, Sergio LE. 2007. Preliminary sex differences in human cortical BOLD fMRI activity during the preparation of increasingly complex visually guided movements. *Eur J Neurosci*. 25:1228-1239.
- Grefkes C, Geyer S, Schormann T, Roland P, Zilles K. 2001. Human somatosensory area 2: observer-independent cytoarchitectonic mapping, interindividual variability, and population map. *Neuroimage*. 14:617-631.
- Hamzei F, Dettmers C, Rijntjes M, Glauche V, Kiebel S, Weber B, Weiller C. 2002. Visuomotor control within a distributed parieto-frontal network. *Exp Brain Res*. 146:273-281.
- Hikosaka O, Tanaka M, Sakamoto M, Iwamura Y. 1985. Deficits in manipulative behaviors induced by local injections of muscimol in the first somatosensory cortex of the conscious monkey. *Brain Res*. 325:375-380.
- Hummel F, Kirsammer R, Gerloff C. 2003. Ipsilateral cortical activation during finger sequences of increasing complexity: representation of movement difficulty or memory load? *Clin Neurophysiol*. 114: 605-613.
- Iacoboni M, Woods RP, Brass M, Bekkering H, Mazziotta JC, Rizzolatti G. 1999. Cortical mechanisms of human imitation. *Science*. 286:2526-2528.
- Johansen-Berg H, Rushworth MFS, Bogdanovic MD, Kischka U, Wimalaratna S, Matthews PM. 2002. The role of ipsilateral premotor cortex in hand movement after stroke. *Proc Natl Acad Sci USA*. 99:14518-14523.
- Jones EG. 1985. Connectivity of the primate sensory-motor cortex. In: Peters A, Jones EG, editors. *Cerebral cortex*. New York: Plenum Press. p. 113-184.
- Koski L, Wohlschlagler A, Bekkering H, Woods RP, Dubeau MC, Mazziotta JC, Iacoboni M. 2002. Modulation of motor and premotor activity during imitation of target-directed actions. *Cereb Cortex*. 12:847-855.
- Lotze M, Markert J, Sauseng P, Hoppe J, Plewnia C, Gerloff C. 2006. The role of multiple contralesional motor areas for complex hand movements after internal capsular lesion. *J Neurosci*. 26:6096-6102.
- Mansur CG, Fregni F, Boggio PS, Riberto M, Gallucci-Neto J, Santos CM, Wagner T, Rigonatti SP, Marcolin MA, Pascual-Leone A. 2005. A sham stimulation-controlled trial of rTMS of the unaffected hemisphere in stroke patients. *Neurology*. 64:1802-1804.
- Mattay VS, Fera F, Tessitore A, Hariri AR, Das S, Callicott JH, Weinberger DR. 2002. Neurophysiological correlates of age-related changes in human motor function. *Neurology*. 58:630-635.
- Mayville JM, Jantzen KJ, Fuchs A, Steinberg FL, Kelso JA. 2002. Cortical and subcortical networks underlying synopated and synchronized coordination revealed using fMRI. *Functional magnetic resonance imaging*. *Hum Brain Mapp*. 17:214-229.
- Medical Research Council (Great Britain). 1976. *Aids to the examination of the peripheral nervous system*. London: H. M. Stationery Office.
- Mesulam MM. 1990. Large-scale neurocognitive networks and distributed processing for attention, language, and memory. *Ann Neurol*. 28:597-613.
- Nair DG, Hutchinson S, Fregni F, Alexander M, Pascual-Leone A, Schlaug G. 2007. Imaging correlates of motor recovery from cerebral infarction and their physiological significance in well-recovered patients. *Neuroimage*. 34:253-263.
- Nelles G, Cramer SC, Schaechter JD, Kaplan JD, Finklestein SP. 1998. Quantitative assessment of mirror movements after stroke. *Stroke*. 29:1182-1187.
- Netz J, Lammers T, Homberg V. 1997. Reorganization of motor output in the non-affected hemisphere after stroke. *Brain*. 120:1579-1586.
- Nishitani N, Hari R. 2000. Temporal dynamics of cortical representation for action. *Proc Natl Acad Sci USA*. 97:913-918.
- Nobre AC, Sebestyen GN, Gitelman DR, Mesulam MM, Frackowiak RS, Frith CD. 1997. Functional localization of the system for visuospatial attention using positron emission tomography. *Brain*. 120:515-533.
- Oldfield RC. 1971. The assessment and analysis of handedness: the Edinburgh inventory. *Neuropsychologia*. 9:97-113.
- Oullier O, Jantzen KJ, Steinberg FL, Kelso JA. 2005. Neural substrates of real and imagined sensorimotor coordination. *Cereb Cortex*. 15: 975-985.
- Ramrani N, Toni I, Passingham RE, Haggard P. 2001. The cerebellum and parietal cortex play a specific role in coordination: a PET study. *Neuroimage*. 14:899-911.
- Rao SM, Binder JR, Bandettini PA, Hammeke TA, Yetkin FZ, Jesmanowicz A, Lisk LM, Morris GL, Mueller WM, Estkowski LD, et al. 1993. Functional magnetic resonance imaging of complex human movements. *Neurology*. 43:2311-2318.
- Sadato N, Campbell G, Ibanez V, Deiber M-P, Hallett M. 1996. Complexity affects regional cerebral blood flow change during sequential finger movements. *J Neurosci*. 16:2693-2700.
- Schaechter JD, Stokes C, Connell BD, Perdue K, Bonmassar G. 2006. Finger motion sensors for fMRI motor studies. *Neuroimage*. 31: 1549-1559.
- Shibasaki H, Sadato N, Lyshkow H, Yonekura Y, Honda M, Nagamine T, Suwazono S, Magata Y, Ikeda A, Miyazaki M, et al. 1993. Both primary motor cortex and supplementary motor area play an important role in complex finger movement. *Brain*. 116:1387-1398.
- Takeuchi N, Chuma T, Matsuo Y, Watanabe I, Ikoma K. 2005. Repetitive transcranial magnetic stimulation of contralesional primary motor cortex improves hand function after stroke. *Stroke*. 36:2681-2686.
- Thesen A, Heid O, Mueller E, Schad LR. 2000. Prospective acquisition correction for head motion with image-based tracking for real-time fMRI. *Magn Reson Med*. 44:457-465.
- Tiffin J, Asher EJ. 1948. The Purdue pegboard: norms and studies of reliability and validity. *J Appl Psychol*. 32:234-247.
- Tomaiuolo F, MacDonald JD, Caramanos Z, Posner G, Chiavaras M, Evans AC, Petrides M. 1999. Morphology, morphometry and probability mapping of the pars opercularis of the inferior frontal gyrus: an in vivo MRI analysis. *Eur J Neurosci*. 11:3033-3046.
- Turton A, Wroe S, Trepte N, Fraser C, Lemon RN. 1996. Contralateral and ipsilateral EMG responses during recovery of arm and hand function after stroke. *Electroencephalogr Clin Neurophysiol*. 101:316-328.
- Twitchell TE. 1951. The restoration of motor function following hemiplegia in man. *Brain*. 74:443-480.
- Verstynen T, Diedrichsen J, Albert N, Aparicio P, Ivry RB. 2005. Ipsilateral motor cortex activity during unimanual hand movements relates to task complexity. *J Neurophysiol*. 93:1209-1222.
- Volkman J, Schnitzler A, Witte OW, Freund H-J. 1998. Handedness and asymmetry of hand representations in human motor cortex. *J Neurophysiol*. 79:2149-2154.
- Waldvogel D, van Gelderen P, Kenji I, Hallett M. 1999. The effect of movement amplitude on activation in functional magnetic resonance imaging studies. *J Cereb Blood Flow Metab*. 19:1209-1212.
- Ward NS, Brown MM, Thompson AJ, Frackowiak RSJ. 2003a. Neural correlates of motor recovery after stroke: a longitudinal fMRI study. *Brain*. 126:2476-2496.
- Ward NS, Brown MM, Thompson AJ, Frackowiak RSJ. 2003b. Neural correlates of outcome after stroke: a cross-sectional fMRI study. *Brain*. 126:1430-1448.
- Ward NS, Frackowiak RS. 2003. Age-related changes in the neural correlates of motor performance. *Brain*. 126:873-888.
- Weiller C, Ramsay SC, Wise RJS, Friston KJ, Frackowiak RSJ. 1993. Individual patterns of functional reorganization in the human cerebral cortex after capsular infarction. *Ann Neurol*. 33:181-189.
- Werhahn KJ, Conforto AB, Kadom N, Hallett M, Cohen LG. 2003. Contribution of the ipsilateral motor cortex to recovery after chronic stroke. *Ann Neurol*. 54:464-472.
- Wewers ME, Lowe NK. 1990. A critical review of visual analogue scales in the measurement of clinical phenomena. *Res Nurs Health*. 13: 227-236.
- Wittenberg GF, Bastian AJ, Dromerick AW, Thach WT, Powers WJ. 2000. Mirror movements complicate interpretation of cerebral activation changes during recovery from subcortical infarction. *Neurorehabil Neural Repair*. 14:213-221.