

The Role of the Fusiform-Amygdala System in the Pathophysiology of Autism

Isabel Dziobek, PhD; Markus Bahnemann, MD; Antonio Convit, MD; Hauke R. Heekeren, MD, PhD

Context: Autism is a condition of unknown origin with well-documented impairments in social perception and cognition.

Objective: To assess the relevance of the fusiform-amygdala system to the pathophysiology of autism spectrum conditions.

Design: Cross-sectional case-control study.

Setting: University hospital.

Participants: A total of 27 adults with autism spectrum conditions and 29 age-, sex-, and intelligence quotient-matched typically developed healthy controls. Patients were assessed according to *DSM-IV* criteria using the Autism Diagnostic Interview-Revised.

Interventions: We applied an automated measurement to estimate fusiform gyrus cortical thickness and a manual tracing method to obtain amygdala volumes. We analyzed volumetric covariance among these brain regions and assessed the functional relevance of anatomi-

cal findings by analyzing correlations with emotional face-processing performance.

Main Outcome Measures: Fusiform gyrus cortical thickness, amygdala volume, emotional face processing.

Results: We found a specific local increase in cortical thickness of the fusiform gyrus and associated impairments in face processing in individuals with autism. Anatomical covariance between amygdala volume and the increase in fusiform gyrus local thickness was significantly smaller in the group with autism spectrum conditions.

Conclusions: Our data provide the first anatomical evidence of an abnormal amygdala-fusiform system and its behavioral relevance to face-processing deficits in autism spectrum conditions. In light of recent evidence of the involvement of the fusiform gyrus and amygdala in social perception as well as the areas of social cognition and emotional awareness, all of which are relevant to autism, our findings might represent a core pathophysiological mechanism of autism.

Arch Gen Psychiatry. 2010;67(4):397-405

Author Affiliations:

Max Planck Institute for Human Development, Berlin, Germany (Drs Dziobek, Bahnemann, and Heekeren); Max Planck Institute for Human Cognitive and Brain Sciences, Leipzig, and Cluster of Excellence, Languages of Emotion, Freie Universität Berlin, Berlin, Germany (Drs Dziobek and Heekeren); Berlin NeuroImaging Center, Department of Neurology, Charité University Medicine Berlin, Berlin, Germany (Drs Bahnemann and Heekeren); and Center for Brain Health, New York University School of Medicine, New York, and Nathan Kline Institute for Psychiatric Research, Orangeburg, New York (Dr Convit).

AUTISM SPECTRUM CONDITIONS (ASC) involve severe abnormalities in social interaction, communication, and repetitive behavior.¹ Deficits in face processing are among the core features of ASC.²⁻⁴ Although these impairments represent only a small fraction of the reported deficits in social perception and social cognition,⁵ their assessment is of particular importance because faces represent a crucial primary source of social information, and their decoding is a precursor for more complex social inference.

In typically developed individuals, face perception involves a distributed set of brain regions comprising a core and an extended system.⁶ The core system mediates the visual analysis of faces and comprises, among other parts, the lateral fusiform gyrus (fusiform face area [FFA]).⁷ The extended system consists of regions acting in concert with the core system to extract

meaning from faces. The amygdala is an important part of this system and plays a central role in processing the social relevance of information gleaned from faces.^{6,8} Animal studies have identified strong reciprocal projections between the amygdala and fusiform gyrus,^{9,10} and recent functional magnetic resonance imaging studies have provided evidence of fusiform activity modulation by the amygdala.¹¹⁻¹³ In fact, viewing emotional faces increases the coupling between the amygdala and fusiform gyrus.¹⁴ Notably, patients with amygdala lesions do not show increased activation in the fusiform cortex when shown fearful faces.¹¹ Together, these findings emphasize that the concerted action of the amygdala and fusiform gyrus is crucial for emotional face processing.

Schultz¹⁵ recently presented a pathophysiological model of autism based on concerted functioning of the amygdala and FFA. This model postulates that a poten-

Table. Demographic Variables of Participants With ASC and Controls

Variable	Mean (SD)		P Value ^a
	ASC (n=27)	Control (n=29)	
Sex			
Male	20	22	.88
Female	7	7	
Age, y	42.0 (11.3)	44.9 (14.6)	.39
Education, y	16.5 (1.6)	16.4 (1.5)	.81
Estimated WAIS-R IQ	111 (8)	113 (7)	.17
Face processing ^b	21.7 (3.4)	25.4 (1.9)	<.001
Mental rotation ^c	17.2 (8.6)	20.2 (9.7)	.23
Spatial visualization ^c	25.7 (8.2)	26.9 (7.1)	.57

Abbreviations: ASC, autism spectrum condition; WAIS-R IQ, Wechsler Adult Intelligence Scale–Revised Intelligence Quotient.

^aP values reflect level of significance from independent samples *t* test and χ^2 as appropriate.

^bMaximum score, 28.

^cMaximum score, 40.

tial congenital abnormality of the amygdala in ASC would lead to a lack of orienting responses to socially salient stimuli such as faces, which would then prevent the development of an expertise for faces mediated by the FFA. In support of that model, structural magnetic resonance imaging studies have provided evidence of amygdala^{16,17} abnormalities in individuals with ASC. In addition, there is recent evidence from voxel-based morphometry studies of increased gray-matter volume in the fusiform gyrus in individuals with ASC.^{18,19} Several functional neuroimaging studies have also shown reduced activation of the FFA^{20,21} and altered amygdala function^{21,22} in individuals with autism during face processing.

Evidence of pathophysiological involvement of the amygdala-fusiform system in ASC can only be convincing, however, if structural changes in this system can be related to functional deficits in social perception and/or social cognition. In the present study, we used a direct measurement of cortical thickness of the fusiform gyrus, given that it might be more sensitive to subtle changes than voxel-based morphometry, which involves confounding factors introduced by normalization,²³ in 27 adults with ASC and 29 controls. To obtain amygdala volumes, we used a well-validated and highly reliable manual tracing method.²⁴ Furthermore, we ascertained anatomical relationships between the fusiform gyrus and the amygdala by analyzing volumetric covariance among those brain regions. Most importantly, to test if the amygdala-fusiform system may indeed provide a valid pathophysiological mechanism for social perceptual impairments in ASC, we analyzed structural-behavioral relationships by including a measure of emotional face recognition.

METHODS

PARTICIPANTS

We recruited 27 adults with ASC (9 with high-functioning autism and 18 with Asperger syndrome; 20 men and 7 women) through local support groups or references from specialized cli-

nicians to participate in the study. Each subject underwent a videotaped diagnostic interview based on which diagnoses of ASC were made according to *DSM-IV* criteria¹ by consensus of 1 psychiatrist (A.C.) and 1 psychologist (I.D.). Diagnostic discrepancies were resolved based on the video material by including a third person trained in diagnosing autism spectrum conditions in adults. In addition, diagnoses were confirmed with the Autism Spectrum Quotient²⁵ and the Autism Diagnostic Interview-Revised (ADI-R)²⁶ in the 18 participants with available parental informants. A group of 29 healthy controls (22 men and 7 women), chosen to match the ASC group as closely as possible with respect to age, education, and intelligence quotient (IQ), also participated in the study (**Table**).

All study participants had medical (including electrocardiogram, blood pressure, and routine blood tests), neurological, neuropsychological, psychiatric, and neuroradiologic (magnetic resonance imaging) examinations. Any present or prior evidence of significant neurological, psychiatric, or medical disease led to exclusion from the study. All participants gave informed written consent, and the research protocol was approved by the local ethics committee.

MEASURES AND STATISTICAL ANALYSIS

Neuropsychology

Intellectual Functioning. To assess intellectual functioning, we used the Shipley Institute of Living Scale,²⁷ comprising a vocabulary and an abstract thinking test. Based on a sum of the raw scores of the tests, we estimated Wechsler Adult Intelligence Scale–Revised IQs.²⁸

Facial Emotion Recognition. Participants were given 28 pictures of facial expressions of happiness, sadness, anger, fear, surprise, disgust, and neutral expressions.²⁹ A word list of these basic emotional states was displayed simultaneously, and the subject was required to correctly identify the displayed emotion.

General Visual Processing. To ascertain the specificity of visual processing impairments to faces, we gave a mental rotation test and a spatial visualization test.³⁰ Specifically, in the mental rotation task, participants were required to mentally rotate letters 0°, 60°, 120°, or 180° to indicate if they were displayed as mirror images for a period of 120 seconds. In the spatial visualization task, participants were asked to count surfaces of increasingly complex 3-dimensional objects for a period of 240 seconds.

Group differences were assessed with independent samples *t* tests. Analyses were 2-tailed and the α level was set at $P < .05$. All statistical procedures were performed using the Statistical Package for the Social Sciences version 15.0 (SPSS Inc, Chicago, Illinois).

Magnetic Resonance Imaging

For all brain measurements, we used a thin-slice, 3-dimensional, coronal, T1-weighted, spoiled gradient recalled sequence. The spoiled gradient recalled sequence parameters were repetition time, 35 milliseconds; echo time, 2 milliseconds; flip angle, 60° and 1 signal average; 124 slices; 1.6-mm slice thickness with no gap; 256 × 128 acquisition matrix; field of view, 200 × 200 mm; and acquisition time, 9 minutes.

Amygdala Measurements

Amygdalae were drawn using TkMedit, an interface in the FreeSurfer toolset (<http://surfer.nmr.mgh.harvard.edu>). TkMedit can be used to navigate through anatomical data and manually cre-

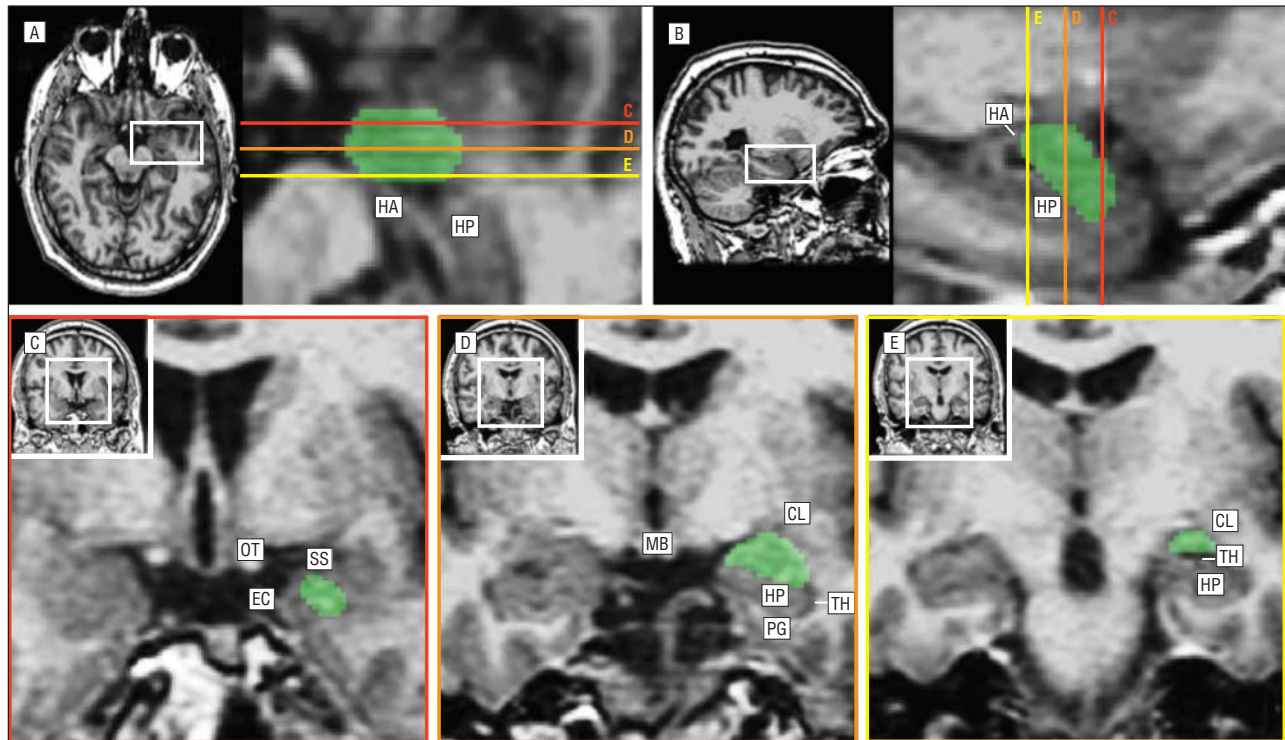


Figure 1. Landmarks used to identify amygdala boundaries. Panels A through E show axial (A), sagittal (B), and coronal (C-E) views of the medial temporal lobe with amygdala tracings and anatomical landmarks. The area included in the amygdala region of interest is indicated by green color. Drawings are displayed on magnified areas from whole-brain sections (white boxes). The colored lines in panels A and B represent anterior (red), middle (orange), and posterior (yellow) sections of the amygdala with corresponding views in coronal orientation in panels C through E. CL indicates claustrum; EC, entorhinal cortex; HA, hippocampo-amygdala transition area; HP, hippocampus; MB, mammillary bodies; OC, optic chiasm; OT, optic tract; PG, parahippocampal gyrus; SS sulcus semiannularis; and TH, temporal horn of the lateral ventricle.

ate 3-dimensional regions of interest (ROIs) that can be written to an external file. TkMedit allows the simultaneous display of coronal, sagittal, and axial views, which greatly simplifies distinguishing the amygdala from surrounding structures. All brain measurements were made blind to group membership.

The method used to estimate amygdala volume has been described in detail in Convit et al²⁴; we briefly outline the method for determining the amygdala boundaries here. The medial border of the amygdala is the angular bundle, which separates it from the entorhinal cortex. More anteriorly, the amygdala border is the sulcus semiannularis, which separates the semilunar gyrus from the ambiens gyrus (entorhinal cortex). The claustrum and head of the caudate are separated from the amygdala gray matter by thin strips of white matter, which represent the superio-lateral borders of the amygdala. The inferior boundary is the hippocampus. The inferio-lateral border of the amygdala is the temporal lobe white matter and the extension of the lateral horn. The posterior boundary is the hippocampal-amygdalar transitional area. The superio-medial border of the amygdala is where the semilunar gyrus comes in contact with the overlying cerebrospinal fluid. The anterior pole is found approximately 7 mm posterior to the frontotemporal junction and about 5 mm behind the anterior limit of the entorhinal cortex.^{31(pp711-755)} Using our method, we obtained high levels of agreement between 2 independent raters (intraclass correlation coefficient=0.93; n=57²⁴) (**Figure 1**).

Cerebral Vault Size Measurements

As a measure of head size, we obtained the intracranial vault volume (ICV). We used a method developed by Buckner and colleagues,³² implemented in the FreeSurfer toolset, that uses the volume scaling factor derived by registering each individual to

an atlas template to automatically generate a good estimate of ICV. The ICV is used as a covariate in our group comparisons to account for the variability in overall brain size, which may have an effect on the size of the brain structures of interest.

Group differences in brain volumes were assessed with independent samples *t* tests. Associations between amygdala volumes and neuropsychological functions were analyzed with Pearson correlation analysis, and differences in correlations between groups were assessed with the Fisher *r*-to-*z* transformation.

Cortical Thickness

Cortical thickness measurements, which are described in detail in Fischl and Dale,³³ were obtained by reconstructing representations of the gray/white matter boundary³⁴ and the cortical surface and then calculating the distance between those surfaces at each vertex across the cortical mantle. This method, which is also part of the FreeSurfer toolset, uses both intensity and continuity information from the entire 3-dimensional magnetic resonance volume in segmentation and deformation procedures to construct representations of cortical thickness. The maps produced are not restricted to the voxel resolution of the original data and, thus, are capable of detecting submillimeter differences between groups.³³ This has been validated using histology and magnetic resonance.^{35,36} Thickness measures may be mapped on the inflated surface of each participant's reconstructed brain.³⁴ Maps were smoothed using a circularly symmetric Gaussian kernel across the surface with a standard deviation of 10 mm and averaged across participants using a nonrigid high-dimensional spherical averaging method to align cortical folding patterns. This procedure provides accurate matching of morphologically homologous cortical locations among participants, resulting in a mean measure of cortical thickness for each group at each point on the recon-

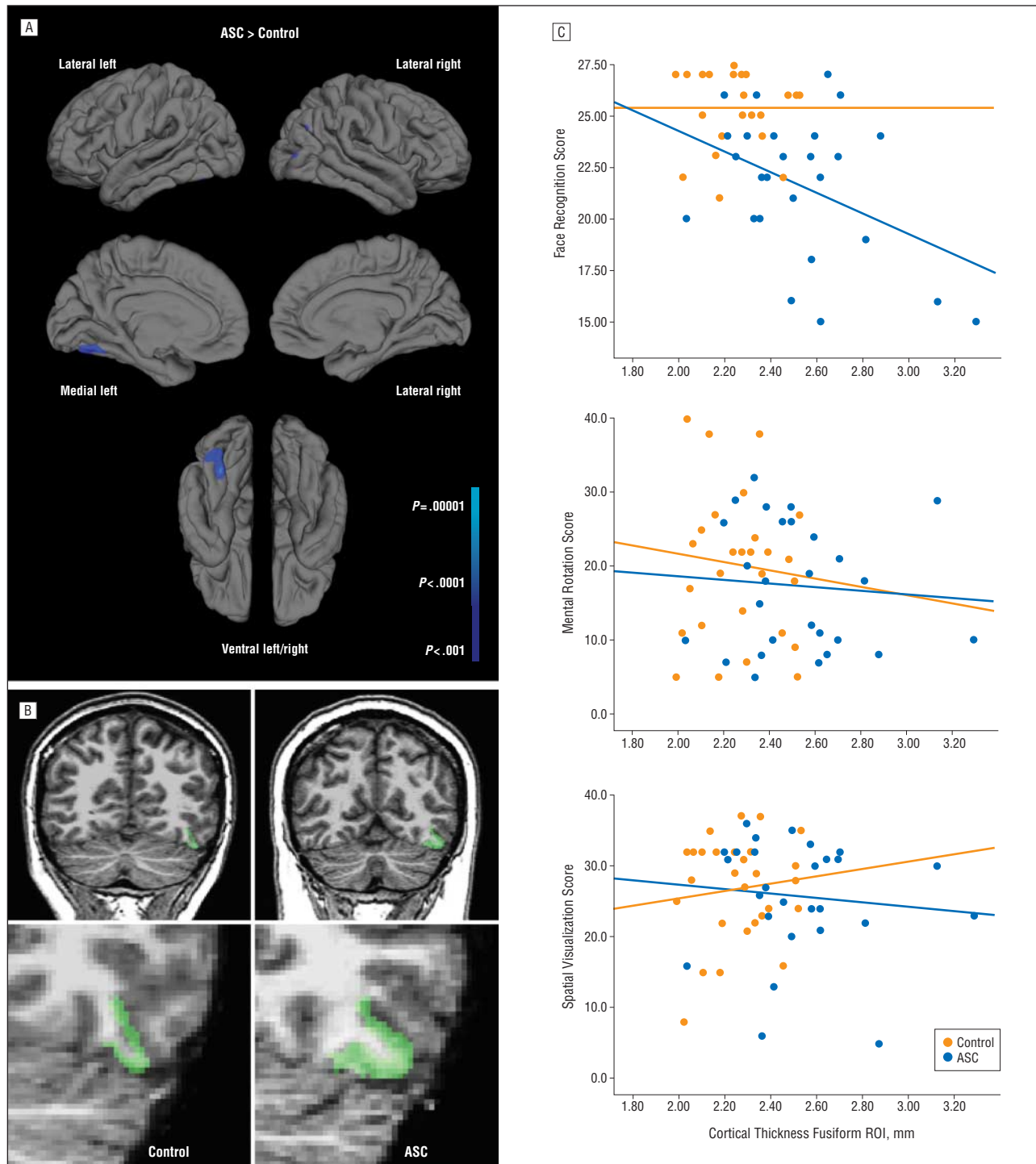


Figure 2. A, Cortical regions are thicker in the autism spectrum condition (ASC) group ($n=27$) than in controls ($n=29$). Statistical maps depict between-group differences in thickness at each vertex on the cortical surface overlaid on the group's average brain. All points meeting a $P < .001$ threshold (uncorrected) are displayed. B, Coronal section displaying area of significant regional thickening for 1 control and 1 participant with ASC. C, Scatterplots of mean cortical thickness of each participant in the left fusiform gyrus region of interest plotted vs face recognition, mental rotation, and spatial visualization, respectively, split by diagnostic group. ROI indicates region of interest.

structed surface. The entire cortex in each participant was visually inspected, and any inaccuracies in segmentation were manually corrected by persons with extensive training in brain anatomy who were blind to group membership. Statistical comparisons of global data and surface maps were generated by computing a general linear model of the effects of each variable on thickness at each vertex. This general linear model analysis revealed increased cortical thickness at the left fusiform gyrus in the ASC

group (see below). This area of regional thickening was used to create an ROI on the group average brain that was mapped back to each individual subject using spherical morphing to find homologous regions across subjects (**Figure 2**). We computed a mean thickness score over the location for each subject and then used these scores to perform Pearson correlation analyses to assess the degree of relationship between cortical thickness and behavioral measures as well as amygdala volume.

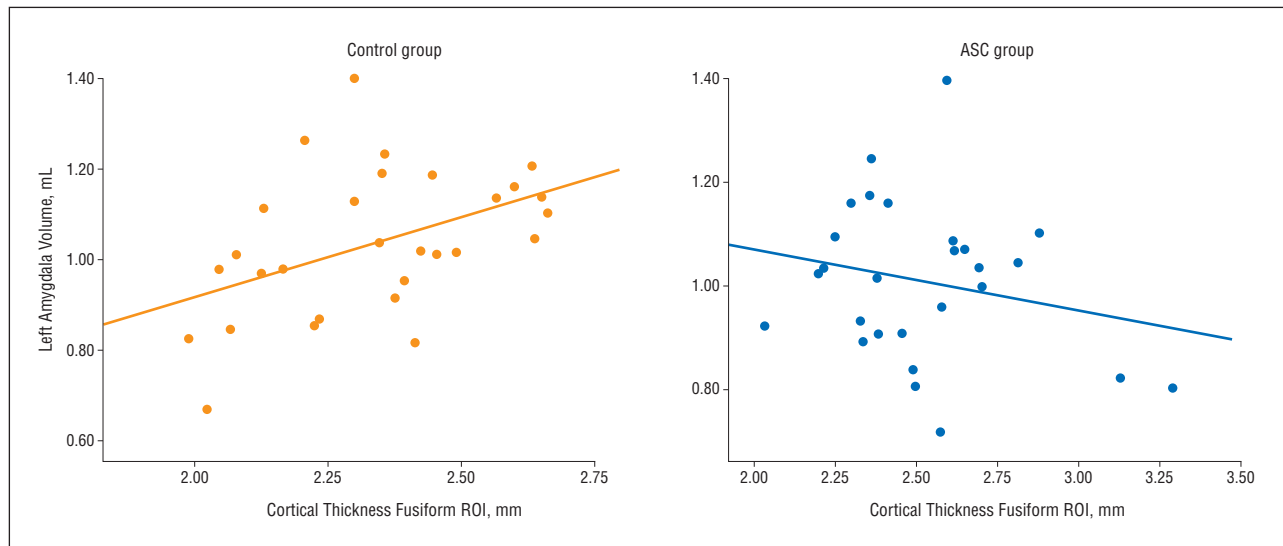


Figure 3. Scatterplots of mean cortical thickness in the left fusiform gyrus region of interest (ROI) plotted vs left amygdala volume for the control ($n=29$; $r=0.44$; $P=.02$) and autism spectrum condition (ASC) ($n=27$; $r=-0.22$; $P=.29$) groups.

RESULTS

BETWEEN-GROUP DIFFERENCES

Demographics and Neuropsychology

The groups were well matched with respect to age, sex, education, and IQ. While the ASC group performance was significantly lower in the facial emotion recognition task, the groups did not differ in either the mental rotation or spatial visualization tests, illustrating that recognition impairments in ASC were specific to faces (Table).

Amygdala Volume and Cortical Thickness

The mean (SD) left and right amygdala volumes for the ASC group were 1.00 (0.15) and 1.04 (0.19) mL, respectively. The control group's mean (SD) left and right amygdala volumes were 1.04 (0.15) and 1.04 (0.22) mL, respectively. Analyses of covariance, controlling for ICV, did not yield any significant group differences in left or right amygdala volumes ($F_{1,53}=0.6$; $P=.46$ and $F_{1,53}=0.0$; $P=1.0$, respectively). The ASC and control groups also did not differ in overall brain size (ICV; $F_{1,54}=0.0$; $P=.96$).

The general linear models comparing the groups showed regional cortical thickening in the ASC participants that was almost exclusively restricted to the mid-posterior part of the left fusiform gyrus (Figure 2). There were no differences indicating thicker cortex for the control group relative to the ASC group.

The clusterwise probability, ie, the probability after correction for multiple comparisons by means of permutation simulations (10 000 iterations), implemented within the FreeSurfer package, was $P=.014$ for the left fusiform gyrus ROI. No other area survived the multiple comparison correction.

Brain-Brain Relationships

To assess anatomical covariance between the amygdala and fusiform gyrus, we computed partial correlations for amygdala volume and mean thickness of the region in the left fusiform gyrus that showed the group difference in the whole-brain analysis for each group individually, while controlling for ICV. In the control group, there was a significant correlation between the left fusiform ROI cortical thickness and left amygdala volume ($r=0.44$, $P=.02$) (Figure 1) but not right amygdala volume ($r=0.17$, $P=.38$). In contrast, in the ASC group we observed negative, albeit not significant, correlations between left fusiform ROI cortical thickness and left amygdala volume ($r=-0.22$, $P=.29$) (Figure 3) as well as right amygdala volume ($r=-0.18$, $P=.37$). The correlations between left fusiform ROI cortical thickness and left amygdala volume were significantly different in the control and ASC groups ($z=2.5$; $P=.01$).

Brain-Behavior Relationships

Next, we tested the behavioral relevance of our anatomical findings to ASC by ascertaining whether left fusiform gyrus ROI cortical thickness could predict behavioral performance in facial emotion recognition. To this end, we performed within-group partial correlation analyses with fusiform cortical thickness and performance scores in tests of face recognition, mental rotation, and spatial visualization after controlling for ICV. As shown in Figure 2C, there were no significant results for any of the correlations in the control group (facial emotion recognition: $r=0.02$, $P=.94$; mental rotation: $r=-0.12$, $P=.53$; spatial visualization: $r=0.08$, $P=.68$). In the ASC group, we found a negative correlation between cortical thickness in the fusiform ROI and facial emotion recognition ($r=-0.41$; $P=.04$). There were no associations between fusiform cortical thickness and general visual process-

ing (mental rotation: $r = -0.06$, $P = .78$; spatial visualization: $r = -0.1$, $P = .64$), illustrating that fusiform gyrus cortical thickness selectively predicted face processing impairments.

COMMENT

In this study, we compared the anatomical properties of the fusiform-amygdala system as well as its behavioral relevance in individuals with autism and well-matched controls. To this end, we used a direct measurement of cortical thickness and a manual tracing method to obtain amygdala volumes.³³ The results provide the first anatomical evidence of an aberrant amygdala-fusiform system with regional cortical thickening of the fusiform gyrus and reduced anatomical covariance between amygdala volume and fusiform gyrus cortical thickness in ASC. Moreover, we discovered that abnormalities in fusiform gyrus cortical thickness predicted face-processing dysfunctions in individuals with ASC, highlighting the behavioral importance of the structural alterations. As such, our results indicate that dysfunction of the amygdala-fusiform system might represent a crucial pathophysiological mechanism of ASC.

In line with previous reports,^{37,38} individuals with ASC have shown deficits in face recognition that were specific, that is, they did not extend to nonface stimuli such as letters or 3-dimensional objects in a mental rotation and spatial visualization task, respectively. Replicating previous reports, we did not find differences in left or right amygdala volumes between the ASC and control group.^{16,39,40} There is, however, convergent evidence of amygdala abnormalities as indicated by neuropathological⁴¹ and functional imaging studies.^{22,42} Moreover, smaller amygdala volume in adults with ASC has been equated with fewer fixations of eye regions, as measured with eye tracking, and more severe social symptomatology, as assessed with the ADI-R.^{43,44}

In adults with ASC, we found a focal increase in cortical thickness of the midposterior portion of the left fusiform gyrus. This finding is consistent with previous voxel-based morphometry studies that found increased gray-matter volume of the left¹⁹ or bilateral fusiform gyrus in high-functioning autistic children and adults,^{18,19} albeit to a much less specific extent. Both studies also reported increased gray-matter density in other regions such as the frontal cortex, caudate nuclei, left hippocampus,¹⁹ and cerebellum.¹⁸ Importantly, both studies reported differences in IQ between the ASC and control groups that were not controlled for and that might have caused the more extensive brain volumetric differences. In contrast, our autism and control groups were well matched for age, sex, and IQ. Thus, the results might be more subtle and specific in the current study.

Two previous studies provided evidence of greater volume of the temporal cortex in individuals with autism. Hardan et al⁴⁵ described greater cortical thickness of the temporal lobes in high-functioning autistic adolescents, without specifying, however, whether this finding involved the fusiform gyrus or other areas within the temporal lobes. In line with our findings, a recent study that volumetrically

assessed the left and right 5 main temporal gyri in individuals with autism and controls identified a bigger left fusiform gyrus volume, among the most important factors in differentiating diagnostic groups.⁴⁶ Another study, however, did not find differences in cortical thickness in the fusiform gyrus in high-functioning adults with ASC.⁴⁷

Although our finding of increased cortical thickness is consistent with the early overall brain volume increase found in autistic individuals,^{48,49} the reasons for this localized thickening are currently unknown. Potential underlying histopathological mechanisms include excess neuron number, excess glia, activated and enlarged glia, excess axon number or dendritic growth, and excess numbers of minicolumns.⁵⁰ A recent study assessed neuron number and density directly in the fusiform gyrus of 7 postmortem brains of individuals with autism and controls.⁵¹ Despite the absence of differences in overall volume of the fusiform gyrus between groups, the authors reported fewer and smaller neurons. Although those data have to be interpreted cautiously given the small sample size and a history of seizure in 3 of the 7 participants with ASC, they seem to indicate that previously suggested mechanisms involving neuronal size or count do not represent likely candidates causing increased volume and cortical thickness, respectively. Instead, abnormalities in glia, axons, or minicolumns are more likely to underlie morphometric increases.

To assess anatomical relationships between the amygdala and fusiform gyrus, we computed within-group partial correlations for amygdala volumes and mean thickness of the left fusiform gyrus ROI, controlling for ICV. We found a negative (although not statistically significant) correlation in the group with autism between left amygdala volume and fusiform cortical thickness, indicating that individuals with smaller amygdala volumes had descriptively increased cortical thickness in the fusiform gyrus, which was associated with greater problems with face processing. This negative association was significantly different from the association in the control group, where we found a positive correlation between amygdala volume and cortical thickness in the fusiform gyrus ROI; control participants with greater amygdala volumes had higher fusiform gyrus ROI cortical thicknesses.

The differences in volumetric covariance clearly reveal an anatomical abnormality within the amygdala-fusiform system in the group with autism. The negative correlation between amygdala volume and fusiform gyrus cortical thickness in the group with autism is in line with a recent study that demonstrated significantly fewer and less positive gray matter volumetric correlations across the brain in individuals with autism.⁵² It has been suggested that anatomical covariance captures an important part of normal brain development. Accordingly, brain volumes of areas subserving common functions are increasingly correlated with age, in line with the maturation of white matter tracts connecting these areas.⁵³ Pathology, on the other hand, alters correlation coefficients within affected networks. Interestingly, morphometric covariance analysis has recently been proposed as an alternative means of studying in vivo brain structural connectivity patterns,⁵⁴⁻⁵⁷ and patterns of volumetric covari-

ance have been shown to correspond with other techniques aimed at investigating anatomical connectivity such as diffusion tensor imaging.⁵⁵ In fact, our anatomical covariance results are in line with a recent diffusion-tensor tracking study that found abnormalities in amygdalo-fusiform pathways in high-functioning autistic adults and adolescents.⁵⁸ In view of this background, we speculate that our results of volumetric associations indicate intact structural connectivity between the amygdala and fusiform gyrus in healthy controls and disruption of that connectivity in individuals with ASC. It will be an important next step to use morphometric correlational analysis, diffusion tensor imaging, and functional neuroimaging methods in combination to further investigate and possibly support this interpretation.

Although of a preliminary nature, our study provides evidence that supports the notion of decreased intracortical connections in autism.⁵⁹ While underconnectivity in ASC has been proposed primarily for higher-order association areas of the brain,⁶⁰ our study suggests a possible extension of this concept to relatively lower-level perceptual systems involving subcortical regions.

Geschwind⁵⁹ has suggested that histogenic events that establish proper positioning and patterning of basic connectivity such as prenatally determined axon pathfinding and postnatally regulated features of dendritic development might be dysregulated in autism. An important task for future studies is to ascertain whether the axonal and dendritic mechanisms that have been suggested to underlie increases in brain volume in ASC⁴⁹ are at the same time instrumental in causing disconnectivity.

The relationship with the left fusiform gyrus ROI was significant only for the left amygdala, which is in line with findings from functional magnetic resonance imaging studies showing that increased responses in the fusiform cortex to fearful faces are abolished by amygdala damage in the ipsilateral rather than contralateral hemisphere.⁶¹ In fact, the reason for selective left fusiform abnormalities in ASC in this and other^{19,46} studies might be owing in part to the lateralization of specific amygdala functions. For example, the left amygdala seems to more specifically process emotions, particularly fear,^{62,63} which is impaired in individuals with autism.⁶⁴

We found that the reduced performance of individuals with ASC in emotional face processing was predicted by increased cortical thickness of the fusiform gyrus. Moreover, the negative associations between facial emotion recognition and fusiform gyrus cortical thickness were specific to face processing; no other tasks of visual processing were related to cortical thickness in either group. This provides further evidence of the relevance of increased cortical thickness of the fusiform gyrus to ASC psychopathology. As such, it not only complements findings of abnormal fusiform gyrus activation when individuals with ASC process faces but might, in fact, be the reason for this activation. Interestingly, while most functional imaging studies have reported reduced activation of the FFA,^{65,66} recent studies have not been able to find such differences^{67,68} or have found that differences were modulated by factors such as the amount of time spent fixating the eyes²¹ or personal familiarity.⁶⁹ Thus, it has been suggested that abnormal fusi-

form functioning and face processing are mediated at least in part by abnormalities in other structures of the social brain, particularly the amygdala.^{15,21,70} Consistent with this, we found that, in addition to a negative correlation between fusiform gyrus cortical thickness and face processing in the ASC group, amygdala volume was related to fusiform gyrus cortical thickness in controls. As such, our results are consistent with the notion that the amygdala acts to increase neural activity in the fusiform gyrus via reciprocal projections,⁹ thereby enhancing the detection and processing of emotionally salient stimuli.⁷¹

Although our study is cross-sectional and no developmental inferences can be drawn, the results support the amygdala-fusiform model of social perceptive impairments in ASC¹⁵ in that both anatomical abnormalities of the amygdala-fusiform system and the ensuing functional impairments of face processing were found in individuals on the autism spectrum. The model also postulates, more speculatively, an important role for the amygdala-fusiform system in social cognition and knowledge and suggests the deficits in social perception in ASC as underlying precursors. For example, tasks requiring social inferences in the absence of faces also activate the fusiform gyrus.^{20,72} Interestingly and further extending this argument, Pessoa et al⁷³ recently reported that awareness of an emotional stimulus is associated with coactivation of the amygdala and fusiform gyrus. In reply to Pessoa's article, Duncan and Barrett⁷⁴ suggested that the amygdala enhances fusiform gyrus activity, thus increasing the likelihood that representations having affective value reach awareness. Altered connectivity between the amygdala and fusiform gyrus, therefore, may not only lead to the impairments in face recognition but also to impairments in emotional awareness as indicated, for example, by higher levels of alexithymia in individuals with ASC.^{75,76}

In conclusion, our data provide the first anatomical evidence of an abnormal amygdala-fusiform system and its behavioral relevance for face processing deficits in ASC. In light of recent evidence of the involvement of the fusiform gyrus and amygdala, not only in social perception but also in the areas of social cognition and emotional awareness, all of which are relevant to autism, our findings might represent a core pathophysiological mechanism of autism. The observation of reduced anatomical covariance in the amygdala-fusiform system in ASC may be interpreted as indicating reduced structural connectivity between these regions. While autism has been theorized as a condition of reduced connectivity in higher-order association cortices, our findings seem to extend this concept to lower-level perceptual systems involving subcortical regions, suggesting disconnectivity as a more universal correlate of ASC brain dysfunction.

Submitted for Publication: January 13, 2009; final revision received August 23, 2009; accepted September 14, 2009.

Correspondence: Hauke R. Heekeren, MD, PhD, Max Planck Institute for Human Development, Lentzeallee 94, 14195 Berlin, Germany (heekeren@mpib-berlin.mpg.de).

Author Contributions: Dr Dziobek had full access to all of the data in the study and takes responsibility for

the integrity of the data and the accuracy of the data analysis.

Financial Disclosure: None reported.

Funding/Support: This study was supported by a grant from the National Alliance for Autism Research; Organization for Autism Research; German Federal Ministry for Research; and the Max Planck Society.

REFERENCES

1. American Psychiatric Association. *Diagnostic and Statistical Manual of Mental Disorders*. 4th ed. Washington, DC: American Psychiatric Association; 1994.
2. Dawson G, Webb S, Schellenberg GD, Dager S, Friedman S, Aylward E, Richards T. Defining the broader phenotype of autism: genetic, brain, and behavioral perspectives. *Dev Psychopathol*. 2002;14(3):581-611.
3. Robel L, Ennouri K, Piana H, Vaivre-Douret L, Perier A, Flament MF, Mouren-Simeoni MC. Discrimination of face identities and expressions in children with autism: same or different? *Eur Child Adolesc Psychiatry*. 2004;13(4):227-233.
4. Pelphrey KA, Sasson NJ, Reznick JS, Paul G, Goldman BD, Piven J. Visual scanning of faces in autism. *J Autism Dev Disord*. 2002;32(4):249-261.
5. Baron-Cohen S, Belmonte MK. Autism: a window onto the development of the social and the analytic brain. *Annu Rev Neurosci*. 2005;28:109-126.
6. Haxby JV, Hoffman EA, Gobbini MI. Human neural systems for face recognition and social communication. *Biol Psychiatry*. 2002;51(1):59-67.
7. Kanwisher N, Yovel G. The fusiform face area: a cortical region specialized for the perception of faces. *Philos Trans R Soc Lond B Biol Sci*. 2006;361(1476):2109-2128.
8. Ishai A. Let's face it: it's a cortical network. *Neuroimage*. 2008;40(2):415-419.
9. Freese JL, Amaral DG. The organization of projections from the amygdala to visual cortical areas TE and V1 in the macaque monkey. *J Comp Neurol*. 2005;486(4):295-317.
10. Freese JL, Amaral DG. Synaptic organization of projections from the amygdala to visual cortical areas TE and V1 in the macaque monkey. *J Comp Neurol*. 2006;496(5):655-667.
11. Vuilleumier P, Richardson MP, Armony JL, Driver J, Dolan RJ. Distant influences of amygdala lesion on visual cortical activation during emotional face processing. *Nat Neurosci*. 2004;7(11):1271-1278.
12. Sabatinelli D, Bradley MM, Fitzsimmons JR, Lang PJ. Parallel amygdala and inferotemporal activation reflect emotional intensity and fear relevance. *Neuroimage*. 2005;24(4):1265-1270.
13. Vuilleumier P, Armony JL, Driver J, Dolan RJ. Effects of attention and emotion on face processing in the human brain: an event-related fMRI study. *Neuron*. 2001;30(3):829-841.
14. Fairhall SL, Ishai A. Effective connectivity within the distributed cortical network for face perception. *Cereb Cortex*. 2007;17(10):2400-2406.
15. Schultz RT. Developmental deficits in social perception in autism: the role of the amygdala and fusiform face area. *Int J Dev Neurosci*. 2005;23(2-3):125-141.
16. Dziobek I, Fleck S, Rogers K, Wolf OT, Convit A. The 'amygdala theory of autism' revisited: linking structure to behavior. *Neuropsychologia*. 2006;44(10):1891-1899.
17. Amaral DG, Schumann CM, Nordahl CW. Neuroanatomy of autism. *Trends Neurosci*. 2008;31(3):137-145.
18. Salmond CH, Vargha-Khadem F, Gadian DG, de Haan M, Baldeweg T. Heterogeneity in the patterns of neural abnormality in autistic spectrum disorders: evidence from ERP and MRI. *Cortex*. 2007;43(6):686-699.
19. Rojas DC, Peterson E, Winterrowd E, Reite ML, Rogers SJ, Tregellas JR. Regional gray matter volumetric changes in autism associated with social and repetitive behavior symptoms. *BMC Psychiatry*. 2006;6:56.
20. Schultz RT, Grelotti DJ, Klin A, Kleinman J, Van der Gaag C, Marois R, Skudlarski P. The role of the fusiform face area in social cognition: implications for the pathobiology of autism. *Philos Trans R Soc Lond B Biol Sci*. 2003;358(1430):415-427.
21. Dalton KM, Nacewicz BM, Johnstone T, Schaefer HS, Gernsbacher MA, Goldsmith HH, Alexander AL, Davidson RJ. Gaze fixation and the neural circuitry of face processing in autism. *Nat Neurosci*. 2005;8(4):519-526.
22. Baron-Cohen S, Ring HA, Wheelwright S, Bullmore ET, Brammer MJ, Simmons A, Williams SC. Social intelligence in the normal and autistic brain: an fMRI study. *Eur J Neurosci*. 1999;11(6):1891-1898.
23. Bookstein FL. "Voxel-based morphometry" should not be used with imperfectly registered images. *Neuroimage*. 2001;14(6):1454-1462.
24. Convit A, McHugh PR, Wolf OT, de Leon MJ, Bobinski M, De Santi S, Roche A, Tsui W. MRI volume of the amygdala: a reliable method allowing separation from the hippocampal formation. *Psychiatry Res*. 1999;90(2):113-123.
25. Baron-Cohen S, Wheelwright S, Skinner R, Martin J, Clubley E. The autism-spectrum quotient (AQ): evidence from Asperger syndrome/high-functioning autism, males and females, scientists and mathematicians. *J Autism Dev Disord*. 2001;31(1):5-17.
26. Lord C, Rutter M, Le Couteur A. Autism diagnostic interview-revised: a revised version of a diagnostic interview for caregivers of individuals with possible pervasive developmental disorders. *J Autism Dev Disord*. 1994;24(5):659-685.
27. Prado WM, Taub DV. Accurate predication of individual intellectual functioning by the Shipley-Hartford. *J Clin Psychol*. 1966;22(3):294-296.
28. Zachary RA, Paulson MJ, Gorsuch RL. Estimating WAIS IQ from the Shipley Institute of Living Scale using continuously adjusted age norms. *J Clin Psychol*. 1985;41(6):820-831.
29. Ekman P, Friesen WV. *Pictures of Facial Affect*. Palo Alto, CA: Consulting Psychologists Press; 1975.
30. Horn W. *Leistungspruefsystem LPS*. Goettingen, Germany: Verlag fuer Psychologie Hogrefe; 1962.
31. Amaral DG, Insausti R, Paxinos G. *Hippocampal Formation: the Human Nervous System*. San Diego, CA: Academic Press Inc; 1990.
32. Buckner RL, Head D, Parker J, Fotenos AF, Marcus D, Morris JC, Snyder AZ. A unified approach for morphometric and functional data analysis in young, old, and demented adults using automated atlas-based head size normalization: reliability and validation against manual measurement of total intracranial volume. *Neuroimage*. 2004;23(2):724-738.
33. Fischl B, Dale AM. Measuring the thickness of the human cerebral cortex from magnetic resonance images. *Proc Natl Acad Sci U S A*. 2000;97(20):11050-11055.
34. Dale AM, Fischl B, Sereno MI. Cortical surface-based analysis I: segmentation and surface reconstruction. *Neuroimage*. 1999;9(2):179-194.
35. Rosas HD, Liu AK, Hersch S, Glessner M, Ferrante RJ, Salat DH, van der Kouwe A, Jenkins BG, Dale AM, Fischl B. Regional and progressive thinning of the cortical ribbon in Huntington's disease. *Neurology*. 2002;58(5):695-701.
36. Kuperberg GR, Broome MR, McGuire PK, David AS, Eddy M, Ozawa F, Goff D, West WC, Williams SC, van der Kouwe AJ, Salat DH, Dale AM, Fischl B. Regionally localized thinning of the cerebral cortex in schizophrenia. *Arch Gen Psychiatry*. 2003;60(9):878-888.
37. Klin A, Sparrow SS, de Bildt A, Cicchetti DV, Cohen DJ, Volkmar FR. A normed study of face recognition in autism and related disorders. *J Autism Dev Disord*. 1999;29(6):499-508.
38. Hauck M, Fein D, Maltby N, Waterhouse L, Feinstein C. Memory for faces in children with autism. *Child Neuropsychol*. 1998;4(3):187-198.
39. Haznedar MM, Buchsbaum MS, Wei TC, Hof PR, Cartwright C, Bienstock CA, Hollander E. Limbic circuitry in patients with autism spectrum disorders studied with positron emission tomography and magnetic resonance imaging. *Am J Psychiatry*. 2000;157(12):1994-2001.
40. Schumann CM, Hamstra J, Goodlin-Jones BL, Lotspeich LJ, Kwon H, Buono-core MH, Lammers CR, Reiss AL, Amaral DG. The amygdala is enlarged in children but not adolescents with autism; the hippocampus is enlarged at all ages. *J Neurosci*. 2004;24(28):6392-6401.
41. Schumann CM, Amaral DG. Stereological analysis of amygdala neuron number in autism. *J Neurosci*. 2006;26(29):7674-7679.
42. Ashwin E, Baron-Cohen S, Wheelwright S, O'Riordan M, Bullmore ET. Differential activation of the amygdala and the 'social brain' during fearful face-processing in Asperger syndrome. *Neuropsychologia*. 2007;45(1):2-14.
43. Nacewicz BM, Dalton KM, Johnstone T, Long MT, McAuliff EM, Oakes TR, Alexander AL, Davidson RJ. Amygdala volume and nonverbal social impairment in adolescent and adult males with autism. *Arch Gen Psychiatry*. 2006;63(12):1417-1428.
44. Munson J, Dawson G, Abbott R, Faja S, Webb SJ, Friedman SD, Shaw D, Artru A, Dager SR. Amygdalar volume and behavioral development in autism. *Arch Gen Psychiatry*. 2006;63(6):686-693.
45. Hardan AY, Muddasani S, Vemulapalli M, Keshavan MS, Minshew NJ. An MRI study of increased cortical thickness in autism. *Am J Psychiatry*. 2006;163(7):1290-1292.
46. Neeley ES, Bigler ED, Krasny L, Ozonoff S, McMahon W, Lainhart JE. Quantitative temporal lobe differences: autism distinguished from controls using classification and regression tree analysis. *Brain Dev*. 2007;29(7):389-399.
47. Hadjikhani N, Joseph RM, Snyder J, Tager-Flusberg H. Anatomical differences in the mirror neuron system and social cognition network in autism. *Cereb Cortex*. 2006;16(9):1276-1282.
48. Courchesne E, Redcay E, Kennedy DP. The autistic brain: birth through adulthood. *Curr Opin Neurol*. 2004;17(4):489-496.
49. Courchesne E. Brain development in autism: early overgrowth followed by premature arrest of growth. *Ment Retard Dev Disabil Res Rev*. 2004;10(2):106-111.
50. Courchesne E, Pierce K, Schumann CM, Redcay E, Buckwalter JA, Kennedy DP,

- Morgan J. Mapping early brain development in autism. *Neuron*. 2007;56(2):399-413.
51. van Kooten IA, Palmen SJ, von Cappeln P, Steinbusch HW, Korr H, Heinsen H, Hof PR, van Engeland H, Schmitz C. Neurons in the fusiform gyrus are fewer and smaller in autism. *Brain*. 2008;131(Pt 4):987-999.
 52. McAlonan GM, Cheung V, Cheung C, Suckling J, Lam GY, Tai KS, Yip L, Murphy DG, Chua SE. Mapping the brain in autism: a voxel-based MRI study of volumetric differences and intercorrelations in autism. *Brain*. 2005;128(pt 2):268-276.
 53. Schmithorst VJ, Wilke M, Dardzinski BJ, Holland SK. Correlation of white matter diffusivity and anisotropy with age during childhood and adolescence: a cross-sectional diffusion-tensor MR imaging study. *Radiology*. 2002;222(1):212-218.
 54. Bullmore ET, Woodruff PW, Wright IC, Rabe-Hesketh S, Howard RJ, Shuriquie N, Murray RM. Does dysplasia cause anatomical dysconnectivity in schizophrenia? *Schizophr Res*. 1998;30(2):127-135.
 55. Lerch JP, Worsley K, Shaw WP, Greenstein DK, Lenroot RK, Giedd J, Evans AC. Mapping anatomical correlations across cerebral cortex (MACACC) using cortical thickness from MRI. *Neuroimage*. 2006;31(3):993-1003.
 56. Mitelman SA, Buchsbaum MS, Brickman AM, Shihabuddin L. Cortical intercorrelations of frontal area volumes in schizophrenia. *Neuroimage*. 2005;27(4):753-770.
 57. Rykhlevskaia E, Gratton G, Fabiani M. Combining structural and functional neuroimaging data for studying brain connectivity: a review. *Psychophysiology*. 2008;45(2):173-187.
 58. Conturo TE, Williams DL, Smith CD, Gultepe E, Akbudak E, Minshew NJ. Neuronal fiber pathway abnormalities in autism: an initial MRI diffusion tensor tracking study of hippocampo-fusiform and amygdalo-fusiform pathways. *J Int Neuropsychol Soc*. 2008;14(6):933-946.
 59. Geschwind DH, Levitt P. Autism spectrum disorders: developmental disconnection syndromes. *Curr Opin Neurobiol*. 2007;17(1):103-111.
 60. Minshew NJ, Williams DL. The new neurobiology of autism: cortex, connectivity, and neuronal organization. *Arch Neurol*. 2007;64(7):945-950.
 61. Vuilleumier P, Pourtois G. Distributed and interactive brain mechanisms during emotion face perception: evidence from functional neuroimaging. *Neuropsychologia*. 2007;45(1):174-194.
 62. Sommer M, Dohnel K, Meinhardt J, Hajak G. Decoding of affective facial expressions in the context of emotional situations. *Neuropsychologia*. 2008;46(11):2615-2621.
 63. Hardee JE, Thompson JC, Puce A. The left amygdala knows fear: laterality in the amygdala response to fearful eyes. *Soc Cogn Affect Neurosci*. 2008;3(1):47-54.
 64. Ashwin E, Chapman E, Colle L, Baron-Cohen S. Impaired recognition of negative basic emotions in autism: a test of the amygdala theory. *Soc Neurosci*. 2006;1(3-4):349-363.
 65. Schultz RT, Gauthier I, Klin A, Fulbright RK, Anderson AW, Volkmar F, Skudlarski P, Lacadie C, Cohen DJ, Gore JC. Abnormal ventral temporal cortical activity during face discrimination among individuals with autism and Asperger syndrome. *Arch Gen Psych*. 2000;57(4):331-340.
 66. Pelphrey KA, Morris JP, McCarthy G, Labar KS. Perception of dynamic changes in facial affect and identity in autism. *Soc Cogn Affect Neurosci*. 2007;2(2):140-149.
 67. Hadjikhani N, Joseph RM, Snyder J, Tager-Flusberg H. Abnormal activation of the social brain during face perception in autism. *Hum Brain Mapp*. 2007;28(5):441-449.
 68. Dapretto M, Davies MS, Pfeifer JH, Scott AA, Sigman M, Bookheimer SY, Iacoboni M. Understanding emotions in others: mirror neuron dysfunction in children with autism spectrum disorders. *Nat Neurosci*. 2006;9(1):28-30.
 69. Pierce K, Redcay E. Fusiform function in children with an ASD is a matter of "who." *Biol Psychiatry*. 2008;64(7):552-560.
 70. Kleinhans NM, Richards T, Sterling L, Stegbauer KC, Mahurin R, Johnson LC, Greenon J, Dawson G, Aylward E. Abnormal functional connectivity in autism spectrum disorders during face processing. *Brain*. 2008;131(pt 4):1000-1012.
 71. Anderson AK, Phelps EA. Lesions of the human amygdala impair enhanced perception of emotionally salient events. *Nature*. 2001;411(6835):305-309.
 72. Kriegstein KV, Giraud AL. Distinct functional substrates along the right superior temporal sulcus for the processing of voices. *Neuroimage*. 2004;22(2):948-955.
 73. Pessoa L, Japee S, Sturman D, Ungerleider LG. Target visibility and visual awareness modulate amygdala responses to fearful faces. *Cereb Cortex*. 2006;16(3):366-375.
 74. Duncan S, Barrett LF. The role of the amygdala in visual awareness. *Trends Cogn Sci*. 2007;11(5):190-192.
 75. Silani G, Bird G, Brindley R, Singer T, Frith C, Frith U. Levels of emotional awareness and autism: an fMRI study. *Soc Neurosci*. 2008;3(2):97-112.
 76. Begeer S, Meerum Terwogt M, Rieffe C, Stegge H, Koot HM. Do children with autism acknowledge the influence of mood on behaviour? *Autism*. 2007;11(6):503-521.