


Contents lists available at [ScienceDirect](#)

NeuroImage

journal homepage: www.elsevier.com/locate/ynimg

Age-associated alterations in cortical gray and white matter signal intensity and gray to white matter contrast

D.H. Salat^{a,b,*}, S.Y. Lee^{a,c}, A.J. van der Kouwe^{a,b}, D.N. Greve^{a,b}, B. Fischl^{a,b,d}, H.D. Rosas^{a,c}

^a Department of Radiology, Massachusetts General Hospital, Boston, MA, USA

^b Athinoula A. Martinos Center for Biomedical Imaging, Massachusetts General Hospital and Harvard Medical School, Boston, MA, USA

^c Department of Neurology, Massachusetts General Hospital, Boston, MA, USA

^d Computer Science and Artificial Intelligence Laboratory, Massachusetts Institute of Technology, Cambridge, MA, USA

ARTICLE INFO

Article history:

Received 5 May 2009

Revised 23 May 2009

Accepted 29 June 2009

Available online xxx

Keywords:

Aging

Cerebral cortex

Cortical thickness

Gray matter

Cortical surface

Tissue contrast

ABSTRACT

Prior studies have focused on patterns of brain atrophy with aging and age-associated cognitive decline. It is possible that changes in neural tissue properties could provide an important marker of more subtle changes compared to gross morphometry. However, little is known about how MRI tissue parameters are altered in aging. We created cortical surface models of 148 individuals and mapped regional gray and white matter T1-weighted signal intensities from 3D MPRAGE images to examine patterns of age-associated signal alterations. Gray matter intensity was decreased with aging with strongest effects in medial frontal, anterior cingulate, and inferior temporal regions. White matter signal intensity decreased with aging in superior and medial frontal, cingulum, and medial and lateral temporal regions. The gray/white ratio (GWR) was altered throughout a large portion of the cortical mantle, with strong changes in superior and inferior frontal, lateral parietal, and superior temporal and precuneus regions demonstrating decreased overall contrast. Statistical effects of contrast changes were stronger than those of cortical thinning. These results demonstrate that there are strong regional changes in neural tissue properties with aging and tissue intensity measures may serve as an important biomarker of degeneration.

Published by Elsevier Inc.

Introduction

Prior studies have demonstrated the effect of aging on several neuroimaging parameters of tissue integrity, including reductions in brain volume (Jernigan et al., 1991, 2001; Lim et al., 1990; Pfefferbaum et al., 1994; Raz et al., 1997; Salat et al., 1999, 2001; Shear et al., 1995; Sullivan et al., 1995), cortical thickness (Fjell et al., 2009; Salat et al., 2004; Ziegler et al., 2008), density (Good et al., 2001; Sowell et al., 2003, 2004) and variation (Thompson et al., 1998), and regional changes in tissue properties such as tissue microstructure measured by diffusion tensor imaging (DTI) (Head et al., 2004; Madden et al., 2009, 2004; Pfefferbaum et al., 2005; Pfefferbaum and Sullivan, 2003; Pfefferbaum et al., 2000; Salat et al., 2005a,b; Sullivan et al., 2001, 2006; Ziegler et al., 2008). Less studied are the reported changes in tissue signal properties, such as T1 relaxation times (Cho et al., 1997; Ogg and Steen, 1998; Raz et al., 1990; Steen et al., 1995) and signal intensity. Similarly, the effect of tissue changes on the contrast properties of neural structures has been almost completely unexplored.

An early study by Raz et al. (1990) examined spin-lattice (T1) relaxation time and found a prolongation in temporal lobe white matter with increasing age. They additionally found that there was a reduction in the differentiation of gray and white matter T1, and this change in contrast was associated with cognitive performance (Raz et al., 1990). A subsequent study by Magnaldi et al. (1993) examined T1, spin density, and T2 values in gray and white matter of 22 individuals. They reported alterations in signal properties with a reduction in gray/white contrast with aging in regions measured. These findings demonstrated that there is a fundamental change in brain tissue with age that alters the imaging properties of brain structures. It is therefore critical to determine the clinical significance of such changes, and whether signal alterations are general or exhibit selective regional patterns. It is also important to understand how changes in tissue properties relate to alterations in neural morphometry to determine whether signal properties may provide a useful biomarker of age and disease-associated histological and pathological properties.

We created cortical surface models in 148 individuals and mapped gray and white matter signal intensities from 3D T1-weighted MPRAGE images to examine the regional patterns of age-associated signal alterations. This type of analysis was previously difficult to perform due to the need for precise representations of the gray/white matter and gray matter/cerebrospinal fluid (CSF) borders. Additionally, such

* Corresponding author. MGH/MIT/HMS Athinoula A. Martinos Center for Biomedical Imaging, MGH Department Radiology, Building 149, 13th St., Mail Code 149 (2301), Charlestown, MA 02129-2060, USA. Fax: +1 617 726 7422.

E-mail address: salat@nmr.mgh.harvard.edu (D.H. Salat).

an analysis requires accurate anatomical matching of data in homologous cortical regions across individuals due to the appreciable regional differences in premorbid gray/white matter signal properties across the cortical mantle, as well as appropriate procedures for the correction for signal nonuniformity. Along with individual tissue class signal intensities, we examined the ratio of gray to white matter signal intensity (GWR) at each point along the cortical surface to determine whether contrast properties were altered in a regionally specific manner throughout the brain. We found strong localized changes in tissue signal properties throughout the cortex and subjacent white matter. The GWR showed a considerable increase (towards a value of 1) with increasing age, demonstrating an overall decrease in the contrast between these tissue classes, mostly due to a decrease in white matter signal intensity approaching that of gray matter. These findings demonstrate that tissue signal properties are altered in nondemented aging in a regionally specific manner. Such changes may be an indirect marker of changes in the histological properties of the tissue that have a significant impact on neural and cognitive processes, and these findings may therefore have important clinical applications.

Materials and methods

Participants

Images were obtained for 148 participants (Table 1). Younger adults (YA) were recruited through the MGH and local community and older adults (OA) were recruited through the Harvard Cooperative Program on Aging (http://www.hebrewrehab.org/home_institute.cfm?id=90) and the Nurses' Health Study (<http://www.channing.harvard.edu/nhs/>) at Harvard Medical School and Brigham and Women's Hospital. OA were screened for dementia using one of the following mental status examinations: the Mini Mental Status Exam (MMSE) (Folstein et al., 1975), the Blessed Dementia Scale (BDS) (Blessed et al., 1968; Stern et al., 1990), or the Telephone Interview of Cognitive Status (TICS) (de Jager et al., 2003; Lipton et al., 2003). Participants were excluded if they had a history of significant neurologic or psychiatric disorder or serious cerebrovascular conditions. Experiments were performed with the understanding and written consent of each participant.

MR acquisition and analysis

Signal properties were examined from high-resolution 3D MPRAGE and cortical reconstruction procedures similar to descriptions in our prior work (Dickerson et al., 2008; Han et al., 2006; Rosas et al., 2008; Salat et al., 2004). We acquired two MPRAGE images (Siemens 1.5 T Avanto System, resolution $1.3 \times 1 \times 1.3$ mm, TR = 2730 ms, TI = 1000 ms, TE = 3.31 ms, FOV 256 mm \times 256 mm (sagittal), matrix 256 \times 192, slice thickness 1.33 mm, 128 slices, bandwidth = 195 Hz/pixel; total acquisition time 8:46) per participant and motion corrected and averaged the scans for a high contrast, high signal to noise volume. Cortical reconstruction was performed

using the FreeSurfer image analysis suite, which is documented and freely available for download online (<http://surfer.nmr.mgh.harvard.edu/>). The technical details of these procedures are described in prior publications (Dale et al., 1999; Dale and Sereno, 1993; Fischl and Dale, 2000; Fischl et al., 2001, 2002, 2004a, 1999a,b, 2004b; Han et al., 2006; Jovicich et al., 2006; Segonne et al., 2004). Briefly, this processing includes removal of non-brain tissue using a hybrid watershed/surface deformation procedure (Segonne et al., 2004), automated Talairach transformation, segmentation of the subcortical white matter and deep gray matter volumetric structures (including hippocampus, amygdala, caudate, putamen, ventricles) (Fischl et al., 2002, 2004a) intensity normalization (Sled et al., 1998), tessellation of the gray matter white matter boundary, automated topology correction (Fischl et al., 2001; Segonne et al., 2007), and surface deformation following intensity gradients to optimally place the gray/white and gray/CSF borders at the location where the greatest shift in intensity defines the transition to the other tissue class (Dale et al., 1999; Dale and Sereno, 1993; Fischl and Dale, 2000). Once the cortical models are complete, a number of deformable procedures can be performed for further data processing and analysis including surface inflation (Fischl et al., 1999a), registration to a spherical atlas which utilizes individual cortical folding patterns to match cortical geometry across subjects (Fischl et al., 1999b), parcellation of the cerebral cortex into units based on gyral and sulcal structure (Desikan et al., 2006; Fischl et al., 2004b), and creation of a variety of surface based data including maps of curvature and sulcal depth. These procedures have been demonstrated to align histological properties such as cytoarchitectonic borders with greater accuracy than volumetric registration (Fischl et al., 2008). This method uses both intensity and continuity information from the entire three dimensional MR volume in segmentation and deformation procedures to produce representations of cortical thickness, calculated as the closest distance from the gray/white boundary to the gray/CSF boundary at each vertex on the tessellated surface (Fischl and Dale, 2000). The maps are created using spatial intensity gradients across tissue classes and are therefore not simply reliant on absolute signal intensity. The maps produced are not restricted to the voxel resolution of the original data and are thus capable of detecting submillimeter differences in thickness between groups. Procedures for the measurement of cortical thickness have been validated against histological analysis (Rosas et al., 2002) and manual measurements (Kuperberg et al., 2003; Salat et al., 2004). FreeSurfer morphometric procedures have been demonstrated to show good test–retest reliability across scanner manufacturers and across field strengths and other imaging parameters (Han et al., 2006; Jovicich et al., 2009; Wonderlick et al., 2008). Images were corrected for intensity nonuniformity prior to sampling tissue intensities (Sled et al., 1998) to reduce the influence of inhomogeneity caused by B1 and coil profiles. In addition to this nonuniformity correction, examination of the GWR provided a highly localized (most voxels within ~ 2 mm) normalization of tissue values because the gray and white matter intensity from closely neighboring voxels would be expected to be similarly influenced by any imaging parameters due to the smoothness of the nuisance parameter maps (e.g. field B0/B1 inhomogeneities) which can be assumed to be smooth relative to the local normalization operation. Thus, presenting the gray matter values as a ratio to bordering white matter values provides a unit which is normalized for the local imaging environment.

Tissue intensities were measured 35% through the thickness of the cortical ribbon, normal to the gray/white border for gray matter, and 1 mm subjacent to the gray/white border along the surface normal for white matter. The 35% sampling procedure was utilized to be conservatively close to the gray/white border and the white matter sampling voxel (which should minimize potential spurious effects that could arise in sampling from more remote locations), and is additionally able to adjust in regions of low cortical thickness (as opposed to using a constant value across the entire border which

Table 1
Participant demographics.

Group	N	Age	Education ^a	MMSE ^b	BDS ^c	TICS ^d
YA	41 (23F/18M)	28.1 \pm 5.2 (20–39)	16.9 \pm 3.1	N/A	N/A	N/A
MA	44 (29F/15M)	49.0 \pm 5.6 (40–59)	16.5 \pm 2.5	N/A	N/A	N/A
OA	63 (49F/14M)	75.5 \pm 7.7 (60–94)	16.5 \pm 2.5	28.9 \pm 1.2	0.88 \pm 1.1	34.5 \pm 2.1

^a Missing education information for 1 YA, 1 OA.

^b N = 32.

^c N = 25.

^d N = 20.

could be problematic for thinner cortical areas). After calculation of the GWR, values were smoothed with a Gaussian kernel of FWHM 30 mm for analysis utilizing a surface based smoothing procedure that averages data across neighboring cortical locations. In contrast to 3D volumetric smoothing, the use of surface based smoothing limited the integration of information to regions limited by the area along the cortical mantle, preventing combining of data across sulcal space and cerebrospinal fluid. Examples of individuals with high and low contrast and mean maps of young adults are demonstrated for gray matter and white matter intensity, and GWR in Fig. 1.

Statistical analysis

The relationships among surface measures (signal intensities, GWR, and thickness) and age were examined with a vertex by vertex general linear model (GLM). A separate GLM was evaluated for each vertex to assess regional variation in each measure. The significance of contrasts of the regression parameters were computed using *t*-tests. In addition to *p* value maps, we created binarized maps demonstrating the unique and overlapping regional patterns of each effect measured.

Results

Age effects on regional intensity and contrast

Gray and white matter intensity showed regional decreases with age. Gray matter effects were found in medial frontal and

anterior cingulate and lateral and inferior temporal regions with smaller effects apparent in frontal cortex. White matter signal decreases were strongest in superior and medial frontal and anterior cingulum regions with lesser effects in inferior temporal regions (Fig. 2). The overlap in gray and white matter signal changes was regionally specific, and the age effects in white matter signal were to a greater spatial extent than gray matter. The GWR significantly increased with age towards a value of 1 in a large portion of frontal regions, as well as inferior parietal, superior temporal, precuneus, and retrosplenial regions demonstrating a reduction in the contrast of these regions (Fig. 3). We next performed a similar analysis looking at the effects of age on regional white matter intensity regressing out gray matter intensity at the adjacent cortical point on the surface. Results of this analysis were similar to the GWR analysis; however the statistical effect was stronger when performing the analysis with this statistical control.

Effects of age on cortical thickness

Cortical thickness decreased most significantly with age in the superior frontal, precentral, postcentral, superior temporal, and occipital regions (Fig. 3). Thinning was also observed in superior parietal cortex and the cuneus. Cortical thickness measures increased with age in the medial frontal regions. These results are similar to results reported in our prior work in independent cohorts (Salat et al., 2004; Ziegler et al., 2008), and are in accord with recent work

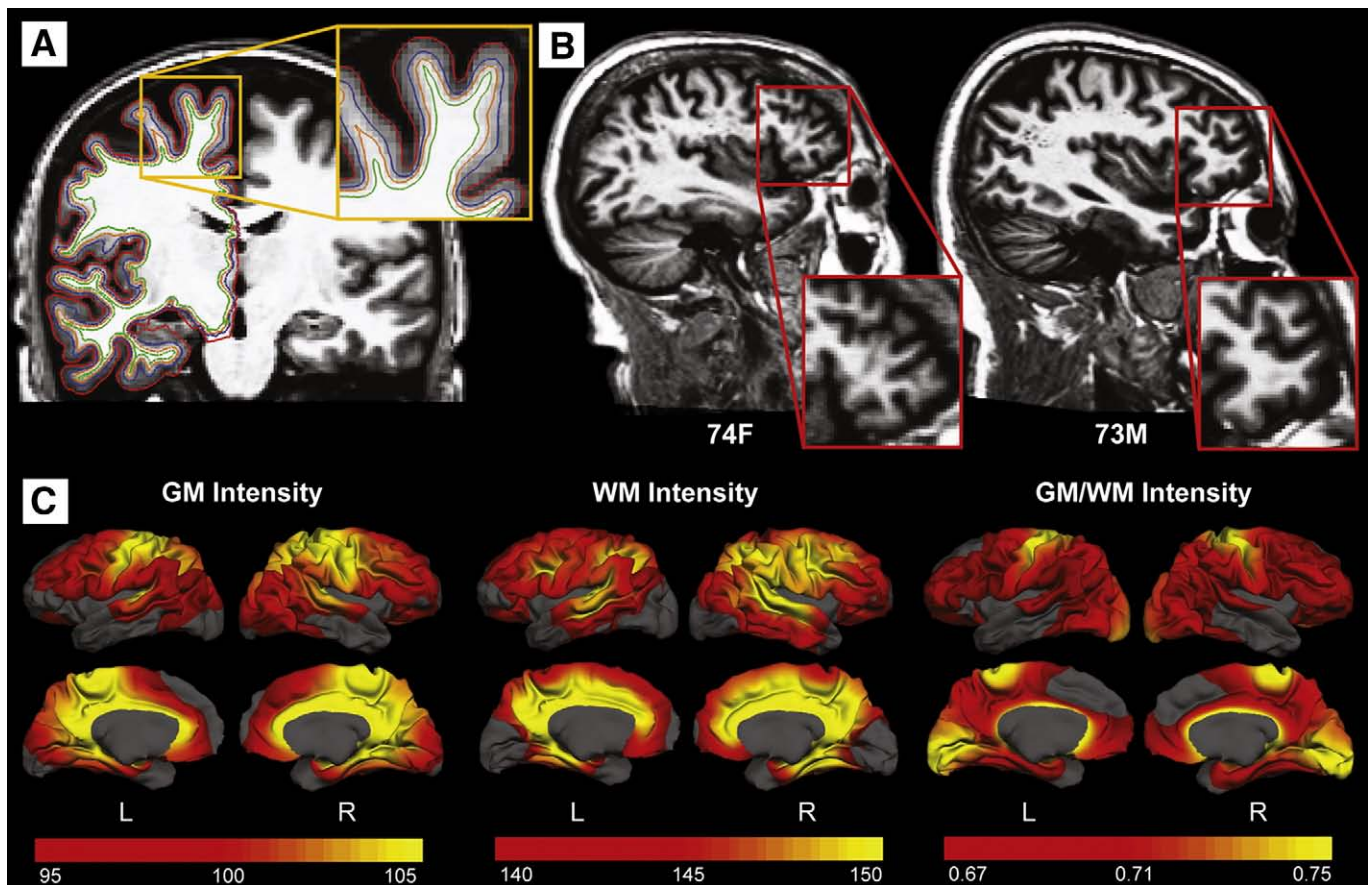


Fig. 1. Tissue sampling method. A. Gray matter was sampled 35% through the total cortical thickness (blue surface; between 1 and 2 mm normal to the gray/white border (orange surface)), and white matter was sampled at a constant distance of 1 mm (green surface). This conservative sampling procedure assured that most measures were obtained from neighboring voxels, or voxels separated by one to two voxels in between. B. An example of an older adult with low contrast (left) and an older adult with high contrast (right) in the same region. C. Mean maps of signal intensities and GWR in young adults demonstrate the variation in these measures across the surface of the cortex.

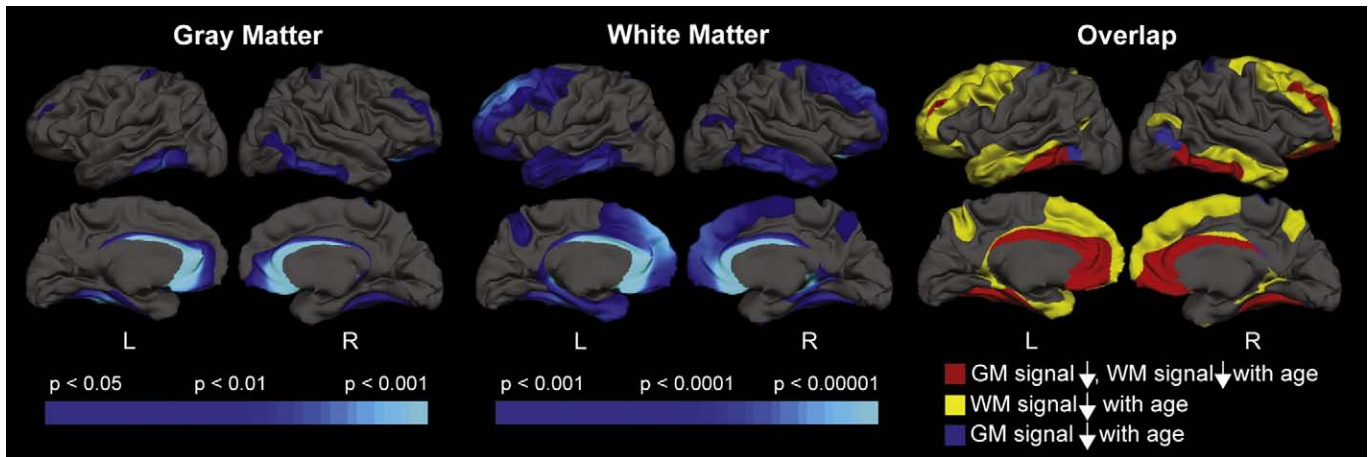


Fig. 2. Effects of age on gray and white matter signal intensities. Gray matter showed a decrease (left panel) and white matter showed a decrease (middle panel) in intensity values with increasing age. Overlap in signal changes was apparent across the two tissue classes (right panel).

describing multi-sample reliability of age-associated cortical thinning (Fjell et al., 2009).

The association between thickness and gray/white contrast

Regional changes in contrast showed appreciable overlap with regions that also showed cortical thinning with aging (yellow areas in Panel B of Fig. 3). We next performed a GLM of the effect of age on GWR regressing out thickness at each vertex along the cortical surface (an individual model for each vertex utilizing the thickness and contrast values at that point). Age-associated changes in contrast remained strong in this analysis (Fig. 3, Panel C). Scatterplots demonstrating selected regions showing differential effects of age on intensity and thickness are presented in Fig. 4.

Sex differences in contrast

There were minimal differences in the GWR between men and women in each age group individually (Fig. 5). Middle-aged adults (MA) showed small differences in right hemisphere parietal regions, and older adults (OA) showed sex differences in the precentral gyrus. When apparent, sex differences were due to men having greater contrast than women.

Reliability of age-associated changes in GWR

We performed a split sample analysis to examine the reliability of the age-associated effects in GWR. To do this, we sorted the entire group by sex and then by age and assigned the odd numbered participants to group A and the even numbered participants to group B to create two equal age and sex-matched samples. The associations between GWR and age were highly reliable across the two samples (Fig. 6), and were in accord with the overall group maps presented in Fig. 3.

Discussion

The current results demonstrate the profound alterations in image properties that occur across the adult age-span. These results have important implications on two levels. First, patterns of signal change are regionally specific, and could be an important metric of neural aging and age-associated neurological disease. It is possible that the changes demonstrated here provide an indirect metric of an essential histological or pathological process, and can therefore be informative in understanding neural development and decline. Second, it is important to understand how the changes in tissue properties reported here could affect technical procedures typically utilized to study brain morphometry with MRI.

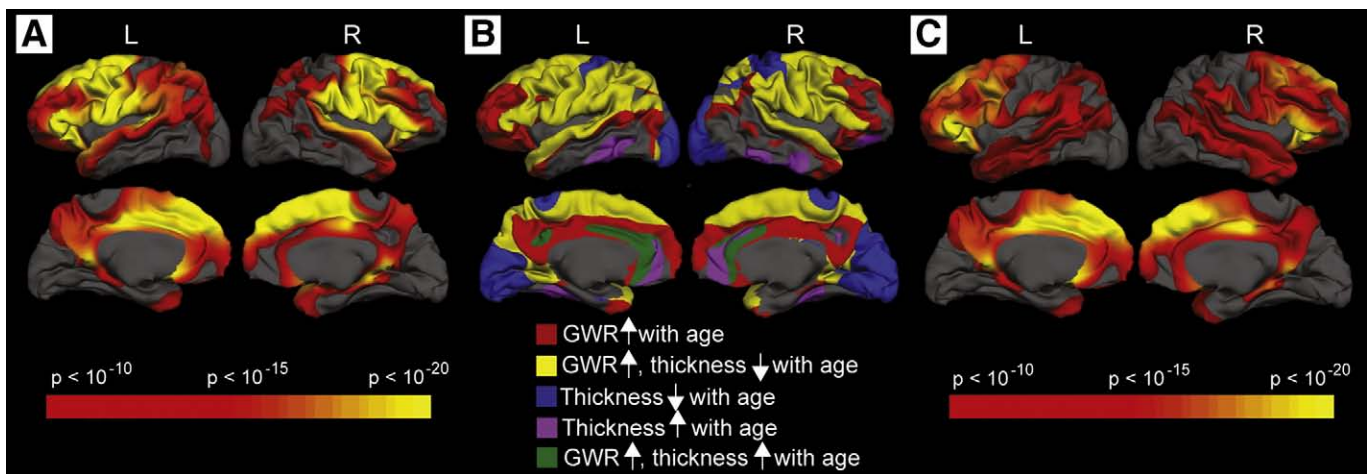


Fig. 3. Effects of age on GWR and cortical thickness. A. Statistical map of the age-associated increase in GWR (age-associated decrease in contrast). B. Maps of the effect of age on cortical thickness were thresholded at $p < 0.01$ and the effect of age on GWR at a much greater significance value ($p < 10^{-10}$) for the creation of overlap maps. Decreases in contrast showed some overlap with age-associated cortical thinning, however, there were regionally distinct effects of GWR increases and of cortical thinning. C. Effects of contrast changes were still apparent after controlling for regional changes in cortical thickness.

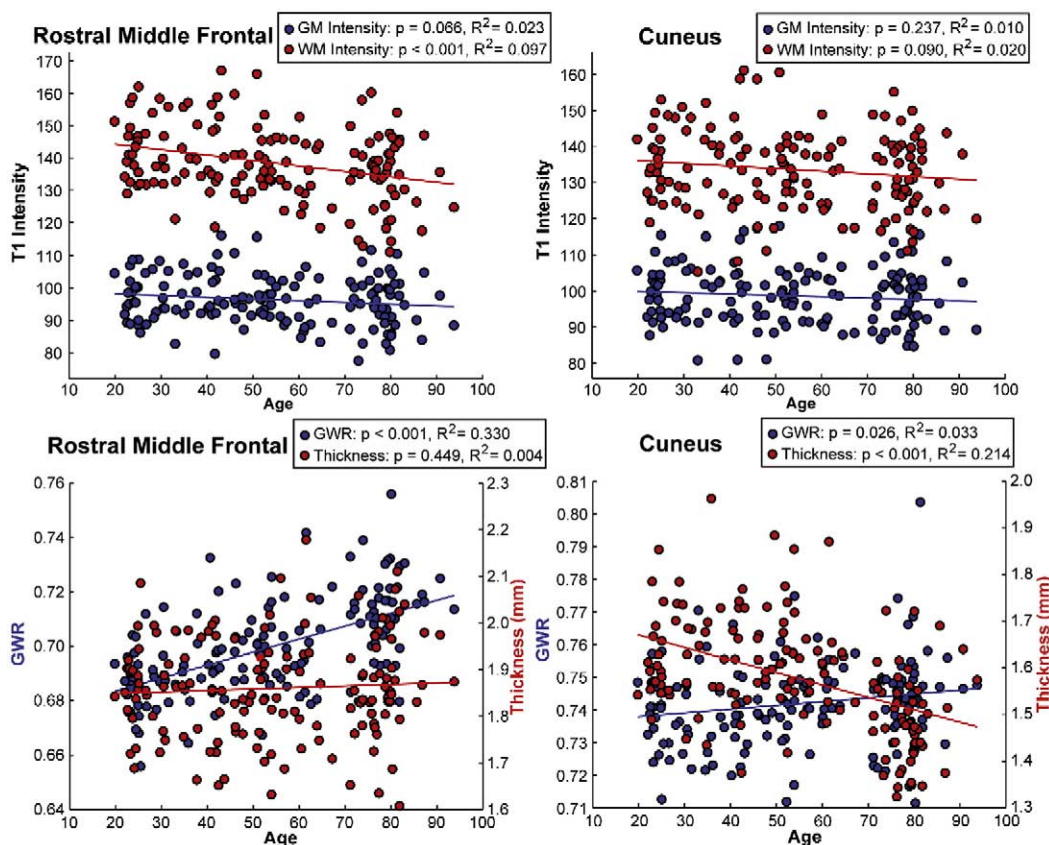


Fig. 4. Scatterplots of selected regional effects in tissue signal. There was a strong reduction in white matter (red circles) but not gray matter (blue circles) intensity with increasing age in the rostral middle frontal gyrus. In contrast, there was minimal change in gray or white matter signal in the cuneus. The reduction in white matter intensity in the rostral middle frontal region with age was accompanied by an increase in the overall GWR towards 1, resulting in a decrease in contrast. Cortical thickness was unaltered in this region. Although signal intensities were relatively unaltered in the cuneus, there was a sharp decline in cortical thickness in this region, demonstrating that although effects overlapped in several regions, there was some regional differentiation of the effects of age on GWR and cortical thickness.

Several prior studies have demonstrated age-associated changes in brain morphometry with various MRI analysis procedures (Fjell et al., 2009; Good et al., 2001; Raz et al., 1997; Salat et al., 2004; Sowell et al., 2004; Ziegler et al., 2008). The current data demonstrate that there are age-associated changes in tissue properties that are regionally specific across the cortical mantle. In many regions, the statistical effect of these changes are greater than those of morphometric changes such as cortical thinning and the effects were statistically (not necessarily biologically) independent. Additionally, it is of interest to

note that changes in contrast were strong in frontal regions where white matter is noted to be particularly affected by age measured with DTI (Head et al., 2004; Pfefferbaum et al., 2005; Pfefferbaum et al., 2000; Salat et al., 2005a,b; Sullivan et al., 2006; Ziegler et al., 2008). The effects were not strongly influenced by sex (although differences were apparent in the middle aged adults). It is possible that signal properties are influenced by tissue changes on a microstructural scale that presage the macrostructural effect of cortical atrophy or white matter tissue degradation. Overall, these findings suggest that

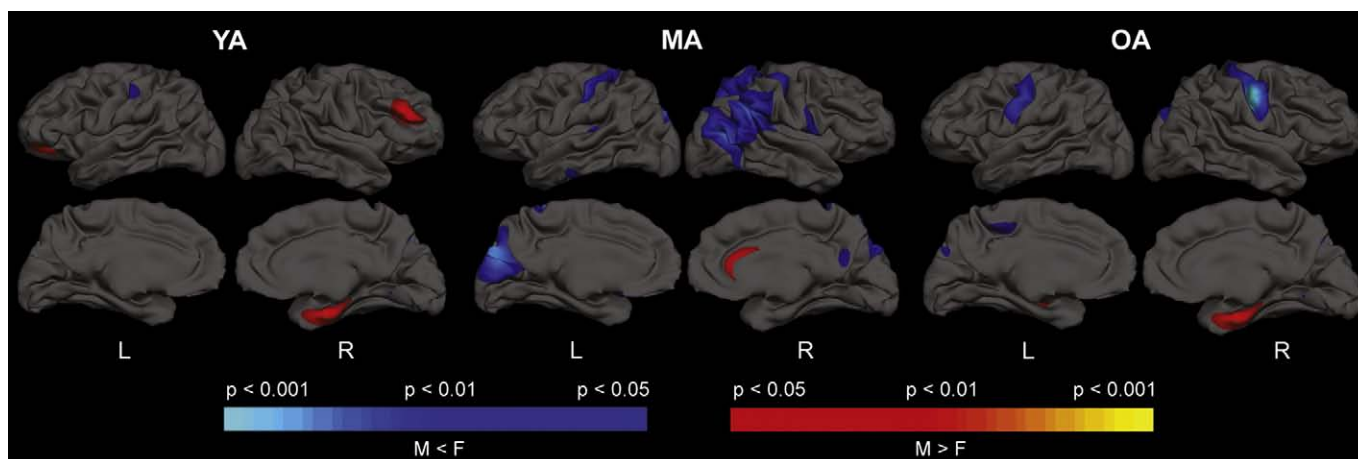


Fig. 5. Sex differences in contrast in each of the three age groups. Sex differences in GWR were minimal in YA (left panel) and OA (right panel). Slightly more substantial effects were apparent in the MA with men having regionally increased contrast compared to women.

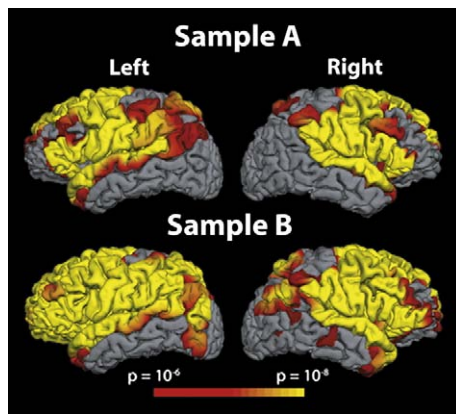


Fig. 6. Reliability of age-associated changes in GWR. A split sample analysis was performed by creating two age and sex-matched independent participant samples and performing the same analysis as described in Fig. 3 on each of the split samples (Split A and Split B). Overall, patterns of age-associated increases in GWR remained strong and were highly regionally consistent across the two samples.

intensity measures may be an important biomarker of aging and age-associated disease. It is therefore possible that intensity and contrast measures may be useful in diagnostic and other clinical procedures. From this perspective, it is interesting to consider how the novel changes measured here may be related to the various aspects of structural and functional brain changes and cognitive decline with aging described in prior work (Cabeza et al., 2002; Chee et al., 2006; Gutchess et al., 2005; Park et al., 2003), as well as recently described models such as Hemispheric Asymmetry Reduction in Older Adults (Cabeza, 2002) and the Scaffolding Theory of Aging (Park and Reuter-Lorenz, 2009).

Prior imaging studies have noted the reduction in gray/white contrast with aging (Jernigan et al., 1991; Magnaldi et al., 1993; Raz et al., 1990). Similar to the current work, these prior studies demonstrated that white matter intensity becomes more like gray matter with age following a quadratic trend (Jernigan et al., 1991; Raz et al., 1990). The mechanisms that contribute to the changes in tissue properties measured here are unknown. Prior studies noted the dependence of T1 relaxation times on regional iron concentration in the brain (Ogg and Steen, 1998), and subtle changes of this sort could contribute to the current results. It is interesting to note, however, that the changes in gray matter signal were regionally distinct from changes in white matter signal in many locations, so such potential accumulation would have to occur in a manner that distinguishes the adjacent tissue classes, at a spatial scale of within approximately 2 to 3 mm (the distance of the sampling procedure). One region, the superior frontal gyrus, showed particularly appreciable signal changes. This regional signal change could be associated with mechanisms that also contribute to the relatively strong age-associated changes in cortical thickness (Salat et al., 2004) and white matter volume (Salat et al., 2008) in this region.

Prior work by Magnaldi et al. (1993) measured the T1, spin density, and T2 values in gray and white matter of 22 individuals. Similar to the current study, they reported a reduction in GWR with aging, and suggested that this change was due to an increase in water content in the white matter and progressive neuronal loss in gray matter. However, more recent studies have emphasized the relative preservation of neurons in the non-diseased aging brain (Morrison and Hof, 1997), and thus, the histological mechanisms of these reported contrast changes are unclear. An alternate explanation is that changes in contrast occur in regions with specific patterns of myelination. This is a potentially strong idea as regional changes in white matter signal intensity exceeded those in gray matter. Other potential contributions could arise from small pathologies such as microinfarcts. It is of note that there are both similarities and

differences between patterns of contrast changes and cortical thinning with advancing age. It is possible that the differential effects in these parameters may represent differences in histologic or pathologic mechanisms, and this question is of great interest for future investigation.

It is important to consider any potential technical contributions of changes in one measure, such as signal properties, to changes in another measure such as cortical thickness. It is possible that changes in cortical thickness influence contrast measures, or alternatively, changes in contrast influence cortical thickness measures. The current data suggest that, although overlapping, these measures are at least to some degree, statistically independent. The FreeSurfer surface procedures use the region of the greatest intensity change to define the border between gray and white matter and surface borders are not dependent on absolute tissue intensity. Thus, border placement should not be greatly affected unless the tissue properties change to such a great degree that the gray/white border is no longer apparent. However, we do not exclude the possibility that contrast changes may affect the border definition based on the intensity gradient to some degree. It is possible that cortical thinning contributed to partial volume contamination in thinner regions; however, this would potentially increase the partial volume fraction from both CSF and subjacent white matter, so it is not clear that this would have biased intensity measures. We examined contrast using a range of sampling procedures to attempt to rule out the effects of technical details. Although the specifics of the sampling do affect the results, the major findings of this study are constant across a range of methods. There is also potential for bias of these procedures in regions of thinner or thicker cortex. We think that this is possible given the different results obtained with different sampling procedures. In particular, it may be difficult to detect effects in very thin cortex where the procedure is sampling gray and white matter from almost the same location. Our analysis regressing out the effects of thickness should control for this potential effect to some degree. As demonstrated in the manuscript, highly significant effects remain after regressing out cortical thickness. We therefore conclude that the signal effects measured and the associations between contrast and thickness are due to biological and only minimally if at all due to technical effects such as shimming and coil sensitivity profiles or technical bias. However, we do not completely rule contributions of the technical parameters to the effects reported. It is important to note that the current results are cross-sectional, and ongoing work will examine the longitudinal effects of age on the GWR. Such analyses will be particularly informative with regard to the use of GWR as a sensitive marker of tissue alterations.

The current study utilized a 3D MPRAGE sequence to define tissue intensities. This is a limitation as this sequence is not quantitative and the signal intensities can be affected by technical aspects of the scanning procedures. Indeed the parameters of the MPRAGE sequence were selected to maximize the sensitivity to differences between gray matter, white matter and CSF intensity per unit of acquisition time. In most scenarios, it would be expected that artifactual effects would be equal in neighboring gray and white matter. We attempted to minimize any imaging confounds through nonuniformity correction procedures. Nonuniformity could be due to dielectric resonance effects (negligible at 1.5 T and small at 3 T) or receive coil profiles. An additional step to minimize this limitation was the examination of the relative metric of gray/white contrast, which should provide a local normalization and not be susceptible to imaging effects. These findings suggest that the lack of a quantitative sequence was not the basis of the results measured. Nevertheless, it is possible that use of a truly quantitative sequence of T1 relaxation times which would be more independent of spin density contributions could provide different results, and we are currently in the process of exploring this question. Similarly, given the greater effects in white matter over gray matter, it will be of strong interest to relate findings from this

work to measures from imaging procedures providing important information about white matter integrity such as DTI and magnetization transfer imaging.

In summary, these results demonstrate strong changes in neural tissue signal properties with aging. These changes statistically exceed those of changes in morphometry, and may be an important biomarker of pathologic changes with aging and disease. Ongoing work will examine the longitudinal effects of age as well as the effect of Alzheimer's disease on gray and white matter signal intensities and contrast across the cortical mantle.

Acknowledgments

This work was supported by the National Institutes of Health [K01AG024898, R01NR010827, P41RR14075, BIRN002, U24RR021382, R01EB001550, R01EB006758, R01NS052585, U54EB005149]; the Athinoula A. Martinos Center for Biomedical Imaging, the Mental Illness and Neuroscience Discovery (MIND) Institute, and The Autism & Dyslexia Project funded by the Ellison Medical Foundation. We are grateful to Christina Onorato for providing assistance with data analysis.

References

- Blessed, G., Tomlinson, B.E., Roth, M., 1968. The association between quantitative measures of dementia and of senile change in the cerebral grey matter of elderly subjects. *Br. J. Psychiatry* 114, 797–811.
- Cabeza, R., 2002. Hemispheric asymmetry reduction in older adults: the HAROLD model. *Psychol. Aging* 17, 85–100.
- Cabeza, R., Anderson, N.D., Locantore, J.K., McIntosh, A.R., 2002. Aging gracefully: compensatory brain activity in high-performing older adults. *NeuroImage* 17, 1394–1402.
- Chee, M.W., Goh, J.O., Venkatraman, V., Tan, J.C., Gutchess, A., Sutton, B., Hebrank, A., Leshikar, E., Park, D., 2006. Age-related changes in object processing and contextual binding revealed using fMRI adaptation. *J. Cogn. Neurosci.* 18, 495–507.
- Cho, S., Jones, D., Reddick, W.E., Ogg, R.J., Steen, R.G., 1997. Establishing norms for age-related changes in proton T1 of human brain tissue in vivo. *Magn. Reson. Imaging* 15, 1133–1143.
- Dale, A.M., Sereno, M.I., 1993. Improved localization of cortical activity by combining EEG and MEG with MRI cortical surface reconstruction: a linear approach. *J. Cogn. Neurosci.* 5, 162–176.
- Dale, A.M., Fischl, B., Sereno, M.I., 1999. Cortical surface-based analysis. I. Segmentation and surface reconstruction. *NeuroImage* 9, 179–194.
- de Jager, C.A., Budge, M.M., Clarke, R., 2003. Utility of TICS-M for the assessment of cognitive function in older adults. *Int. J. Geriatr. Psychiatry* 18, 318–324.
- Desikan, R.S., Segonne, F., Fischl, B., Quinn, B.T., Dickerson, B.C., Blacker, D., Buckner, R.L., Dale, A.M., Maguire, R.P., Hyman, B.T., Albert, M.S., Killiany, R.J., 2006. An automated labeling system for subdividing the human cerebral cortex on MRI scans into gyral based regions of interest. *NeuroImage* 31, 968–980.
- Dickerson, B.C., Fenstermacher, E., Salat, D.H., Wolk, D.A., Maguire, R.P., Desikan, R., Pacheco, J., Quinn, B.T., Van der Kouwe, A., Greve, D.N., Blacker, D., Albert, M.S., Killiany, R.J., Fischl, B., 2008. Detection of cortical thickness correlates of cognitive performance: reliability across MRI scan sessions, scanners, and field strengths. *NeuroImage* 39, 10–18.
- Fischl, B., Dale, A.M., 2000. Measuring the thickness of the human cerebral cortex from magnetic resonance images. *Proc. Natl. Acad. Sci. U. S. A.* 97, 11050–11055.
- Fischl, B., Sereno, M.I., Dale, A.M., 1999a. Cortical surface-based analysis. II: Inflation, flattening, and a surface-based coordinate system. *NeuroImage* 9, 195–207.
- Fischl, B., Sereno, M.I., Tootell, R.B., Dale, A.M., 1999b. High-resolution intersubject averaging and a coordinate system for the cortical surface. *Hum. Brain Mapp.* 8, 272–284.
- Fischl, B., Liu, A., Dale, A.M., 2001. Automated manifold surgery: constructing geometrically accurate and topologically correct models of the human cerebral cortex. *IEEE Trans. Med. Imag.* 20, 70–80.
- Fischl, B., Salat, D.H., Busa, E., Albert, M., Dieterich, M., Haselgrove, C., van der Kouwe, A., Killiany, R., Kennedy, D., Klaveness, S., Montillo, A., Makris, N., Rosen, B., Dale, A.M., 2002. Whole brain segmentation: automated labeling of neuroanatomical structures in the human brain. *Neuron* 33, 341–355.
- Fischl, B., Salat, D.H., van der Kouwe, A.J., Makris, N., Segonne, F., Quinn, B.T., Dale, A.M., 2004a. Sequence-independent segmentation of magnetic resonance images. *NeuroImage* 23 (Suppl. 1), S69–84.
- Fischl, B., van der Kouwe, A., Destrieux, C., Halgren, E., Segonne, F., Salat, D.H., Busa, E., Seidman, L.J., Goldstein, J., Kennedy, D., Caviness, V., Makris, N., Rosen, B., Dale, A.M., 2004b. Automatically parcellating the human cerebral cortex. *Cereb. Cortex* 14, 11–22.
- Fischl, B., Rajendran, N., Busa, E., Augustinack, J., Hinds, O., Yeo, B.T., Mohlberg, H., Amunts, K., Zilles, K., 2008. Cortical folding patterns and predicting cytoarchitecture. *Cereb. Cortex* 18, 1973–1980.
- Fjell, A.M., Westlye, L.T., Amlien, I., Espeseth, T., Reinvang, I., Raz, N., Agartz, I., Salat, D.H., Greve, D.N., Fischl, B., Dale, A.M., Walhovd, K.B., 2009. High consistency of regional cortical thinning in aging across multiple samples. *Cereb. Cortex*.
- Folstein, M.F., Folstein, S.E., McHugh, P.R., 1975. "Mini-mental state": A practical method for grading the cognitive state of patients for the clinician. *J. Psychiatr. Res.* 12, 189–198.
- Good, C.D., Johnsrude, I.S., Ashburner, J., Henson, R.N., Friston, K.J., Frackowiak, R.S., 2001. A voxel-based morphometric study of ageing in 465 normal adult human brains. *NeuroImage* 14, 21–36.
- Gutchess, A.H., Welsh, R.C., Hedden, T., Bangert, A., Minear, M., Liu, L.L., Park, D.C., 2005. Aging and the neural correlates of successful picture encoding: frontal activations compensate for decreased medial-temporal activity. *J. Cogn. Neurosci.* 17, 84–96.
- Han, X., Jovicich, J., Salat, D., van der Kouwe, A., Quinn, B., Czanner, S., Busa, E., Pacheco, J., Albert, M., Killiany, R., Maguire, P., Rosas, D., Makris, N., Dale, A., Dickerson, B., Fischl, B., 2006. Reliability of MRI-derived measurements of human cerebral cortical thickness: the effects of field strength, scanner upgrade and manufacturer. *NeuroImage* 32, 180–194.
- Head, D., Buckner, R.L., Shimony, J.S., Williams, L.E., Akbudak, E., Conturo, T.E., McAvoy, M., Morris, J.C., Snyder, A.Z., 2004. Differential vulnerability of anterior white matter in nondemented aging with minimal acceleration in dementia of the Alzheimer type: evidence from diffusion tensor imaging. *Cereb. Cortex* 14, 410–423.
- Jernigan, T.L., Archibald, S.L., Berhow, M.T., Sowell, E.R., Foster, D.S., Hesselink, J.R., 1991. Cerebral structure on MRI, part I: localization of age-related changes. *Biol. Psychiatry* 29, 55–67.
- Jernigan, T.L., Archibald, S.L., Fennema-Notestine, C., Gamst, A.C., Stout, J.C., Bonner, J., Hesselink, J.R., 2001. Effects of age on tissues and regions of the cerebrum and cerebellum. *Neurobiol. Aging* 22, 581–594.
- Jovicich, J., Czanner, S., Greve, D., Haley, E., van der Kouwe, A., Gollub, R., Kennedy, D., Schmitt, F., Brown, G., Macfall, J., Fischl, B., Dale, A., 2006. Reliability in multi-site structural MRI studies: effects of gradient non-linearity correction on phantom and human data. *NeuroImage* 30, 436–443.
- Jovicich, J., Czanner, S., Han, X., Salat, D., van der Kouwe, A., Quinn, B., Pacheco, J., Albert, M., Killiany, R., Blacker, D., Maguire, P., Rosas, D., Makris, N., Gollub, R., Dale, A., Dickerson, B.C., Fischl, B., 2009. MRI-derived measurements of human subcortical, ventricular and intracranial brain volumes: reliability effects of scan sessions, acquisition sequences, data analyses, scanner upgrade, scanner vendors and field strengths. *NeuroImage* 46, 177–192.
- Kuperberg, G.R., Broome, M.R., McGuire, P.K., David, A.S., Eddy, M., Ozawa, F., Goff, D., West, W.C., Williams, S.C., van der Kouwe, A.J., Salat, D.H., Dale, A.M., Fischl, B., 2003. Regionally localized thinning of the cerebral cortex in schizophrenia. *Arch. Gen. Psychiatry* 60, 878–888.
- Lim, K.O., Zipursky, R.B., Murphy Jr., G.M., Pfefferbaum, A., 1990. In vivo quantification of the limbic system using MRI: effects of normal aging. *Psychiatry Res.* 35, 15–26.
- Lipton, R.B., Katz, M.J., Kuslansky, G., Sliwinski, M.J., Stewart, W.F., Verghese, J., Crystal, H.A., Buschke, H., 2003. Screening for dementia by telephone using the memory impairment screen. *J. Am. Geriatr. Soc.* 51, 1382–1390.
- Madden, D.J., Whiting, W.L., Huettel, S.A., White, L.E., MacFall, J.R., Provenzale, J.M., 2004. Diffusion tensor imaging of adult age differences in cerebral white matter: relation to response time. *NeuroImage* 21, 1174–1181.
- Madden, D.J., Spaniol, J., Costello, M.C., Bucur, B., White, L.E., Cabeza, R., Davis, S.W., Dennis, N.A., Provenzale, J.M., Huettel, S.A., 2009. Cerebral white matter integrity mediates adult age differences in cognitive performance. *J. Cogn. Neurosci.* 21, 289–302.
- Magnaldi, S., Ukmar, M., Vasciaveo, A., Longo, R., Pozzi-Mucelli, R.S., 1993. Contrast between white and grey matter: MRI appearance with ageing. *Eur. Radiol.* 513–519.
- Morrison, J.H., Hof, P.R., 1997. Life and death of neurons in the aging brain. *Science* 278, 412–419.
- Ogg, R.J., Steen, R.G., 1998. Age-related changes in brain T1 are correlated with iron concentration. *Magn. Reson. Med.* 40, 749–753.
- Park, D.C., Reuter-Lorenz, P., 2009. The adaptive brain: aging and neurocognitive scaffolding. *Annu. Rev. Psychol.* 60, 173–196.
- Park, D.C., Welsh, R.C., Marshuetz, C., Gutchess, A.H., Mikels, J., Polk, T.A., Noll, D.C., Taylor, S.F., 2003. Working memory for complex scenes: age differences in frontal and hippocampal activations. *J. Cogn. Neurosci.* 15, 1122–1134.
- Pfefferbaum, A., Sullivan, E.V., 2003. Increased brain white matter diffusivity in normal adult aging: relationship to anisotropy and partial voluming. *Magn. Reson. Med.* 49, 953–961.
- Pfefferbaum, A., Mathalon, D.H., Sullivan, E.V., Rawles, J.M., Zipursky, R.B., Lim, K.O., 1994. A quantitative magnetic resonance imaging study of changes in brain morphology from infancy to late adulthood. *Arch. Neurol.* 51, 874–887.
- Pfefferbaum, A., Sullivan, E.V., Hedehus, M., Lim, K.O., Adalsteinsson, E., Moseley, M., 2000. Age-related decline in brain white matter anisotropy measured with spatially corrected echo-planar diffusion tensor imaging. *Magn. Reson. Med.* 44, 259–268.
- Pfefferbaum, A., Adalsteinsson, E., Sullivan, E.V., 2005. Frontal circuitry degradation marks healthy adult aging: evidence from diffusion tensor imaging. *NeuroImage* 26, 891–899.
- Raz, N., Millman, D., Sarpel, G., 1990. Cerebral correlates of cognitive aging: gray-white-matter differentiation in the medial temporal lobes, and fluid versus crystallized abilities. *Psychobiology* 18, 475–481.
- Raz, N., Gunning, F.M., Head, D., Dupuis, J.H., McQuain, J., Briggs, S.D., Loken, W.J., Thornton, A.E., Acker, J.D., 1997. Selective aging of the human cerebral cortex observed in vivo: differential vulnerability of the prefrontal gray matter. *Cereb. Cortex* 7, 268–282.
- Rosas, H.D., Liu, A.K., Hersch, S., Glessner, M., Ferrante, R.J., Salat, D.H., van der Kouwe, A., Jenkins, B.G., Dale, A.M., Fischl, B., 2002. Regional and progressive thinning of the cortical ribbon in Huntington's disease. *Neurology* 58, 695–701.

- Rosas, H.D., Salat, D.H., Lee, S.Y., Zaleta, A.K., Pappu, V., Fischl, B., Greve, D., Hevelone, N., Hersch, S.M., 2008. Cerebral cortex and the clinical expression of Huntington's disease: complexity and heterogeneity. *Brain* 131, 1057–1068.
- Salat, D.H., Kaye, J.A., Janowsky, J.S., 1999. Prefrontal gray and white matter volumes in healthy aging and Alzheimer disease. *Arch. Neurol.* 56, 338–344.
- Salat, D.H., Kaye, J.A., Janowsky, J.S., 2001. Selective preservation and degeneration within the prefrontal cortex in aging and Alzheimer disease. *Arch. Neurol.* 58, 1403–1408.
- Salat, D.H., Buckner, R.L., Snyder, A.Z., Greve, D.N., Desikan, R.S., Busa, E., Morris, J.C., Dale, A.M., Fischl, B., 2004. Thinning of the cerebral cortex in aging. *Cereb. Cortex* 14, 721–730.
- Salat, D.H., Tuch, D.S., Greve, D.N., van der Kouwe, A.J., Hevelone, N.D., Zaleta, A.K., Rosen, B.R., Fischl, B., Corkin, S., Rosas, H.D., Dale, A.M., 2005a. Age-related alterations in white matter microstructure measured by diffusion tensor imaging. *Neurobiol. Aging* 26, 1215–1227.
- Salat, D.H., Tuch, D.S., Hevelone, N.D., Fischl, B., Corkin, S., Rosas, H.D., Dale, A.M., 2005b. Age-related changes in prefrontal white matter measured by diffusion tensor imaging. *Ann. N.Y. Acad. Sci.* 1064, 37–49.
- Salat, D.H., Greve, D.N., Pacheco, J.L., Quinn, B.T., Helmer, K.G., Buckner, R.L., Fischl, B., 2008. Regional white matter volume differences in nondemented aging and Alzheimer's disease. *NeuroImage*.
- Segonne, F., Dale, A.M., Busa, E., Glessner, M., Salat, D., Hahn, H.K., Fischl, B., 2004. A hybrid approach to the skull stripping problem in MRI. *NeuroImage* 22, 1060–1075.
- Segonne, F., Pacheco, J., Fischl, B., 2007. Geometrically accurate topology-correction of cortical surfaces using nonseparating loops. *IEEE Trans. Med. Imag.* 26, 518–529.
- Shear, P.K., Sullivan, E.V., Mathalon, D.H., Lim, K.O., Davis, L.F., Yesavage, J.A., Tinklenberg, J.R., Pfefferbaum, A., 1995. Longitudinal volumetric computed tomographic analysis of regional brain changes in normal aging and Alzheimer's disease. *Arch. Neurol.* 52, 392–402.
- Sled, J.G., Zijdenbos, A.P., Evans, A.C., 1998. A nonparametric method for automatic correction of intensity nonuniformity in MRI data. *IEEE Trans. Med. Imag.* 17, 87–97.
- Sowell, E.R., Peterson, B.S., Thompson, P.M., Welcome, S.E., Henkenius, A.L., Toga, A.W., 2003. Mapping cortical change across the human life span. *Nat. Neurosci.* 6, 309–315.
- Sowell, E.R., Thompson, P.M., Toga, A.W., 2004. Mapping changes in the human cortex throughout the span of life. *Neuroscientist* 10, 372–392.
- Steen, R.G., Gronemeyer, S.A., Taylor, J.S., 1995. Age-related changes in proton T1 values of normal human brain. *J. Magn. Reson. Imag.* 5, 43–48.
- Stern, Y., Hesdorffer, D., Sano, M., Mayeux, R., 1990. Measurement and prediction of functional capacity in Alzheimer's disease. *Neurology* 40, 8–14.
- Sullivan, E.V., Marsh, L., Mathalon, D.H., Lim, K.O., Pfefferbaum, A., 1995. Age-related decline in MRI volumes of temporal lobe gray matter but not hippocampus. *Neurobiol. Aging* 16, 591–606.
- Sullivan, E.V., Adalsteinsson, E., Hedehus, M., Ju, C., Moseley, M., Lim, K.O., Pfefferbaum, A., 2001. Equivalent disruption of regional white matter microstructure in ageing healthy men and women. *NeuroReport* 12, 99–104.
- Sullivan, E.V., Adalsteinsson, E., Pfefferbaum, A., 2006. Selective age-related degradation of anterior callosal fiber bundles quantified in vivo with fiber tracking. *Cereb. Cortex* 16, 1030–1039.
- Thompson, P.M., Moussai, J., Zohoori, S., Goldkorn, A., Khan, A.A., Mega, M.S., Small, G.W., Cummings, J.L., Toga, A.W., 1998. Cortical variability and asymmetry in normal aging and Alzheimer's disease. *Cereb. Cortex* 8, 492–509.
- Wonderlick, J.S., Ziegler, D.A., Hosseini-Varnamkhandi, P., Locascio, J.J., Bakkour, A., van der Kouwe, A., Triantafyllou, C., Corkin, S., Dickerson, B.C., 2008. Reliability of MRI-derived cortical and subcortical morphometric measures: effects of pulse sequence, voxel geometry, and parallel imaging. *NeuroImage*.
- Ziegler, D.A., Piguet, O., Salat, D.H., Prince, K., Connally, E., Corkin, S., 2008. Cognition in healthy aging is related to regional white matter integrity, but not cortical thickness. *Neurobiol. Aging*.